

Tuberculosis of wrist joint in a patient with Rheumatoid Arthritis on conventional DMARDS- useful function despite gross bony destruction at 3 years follow up

Naba Pallab Chetia¹, Sagarika Gogoi², Aritra Bidyananda^{3,*}, Monoranjan Howbora⁴

¹Assistant Professor, ^{3,4}Post Graduate Students, Dept. of Orthopaedics, ²Registrar, Dept. of Dermatology, Assam Medical College & Hospital, Dibrugarh, Assam

***Corresponding Author:**

Email: aritra.bidyananda@gmail.com

Abstract

In some developing countries, patients undergoing treatment of Rheumatoid Arthritis (RA) with biological agent have a substantial increase in the incidence of tuberculosis (TB). But incidence of specific association of skeletal tuberculosis in RA patient on conventional DMARDS is not specifically mentioned in the literature. We present a case of a lady who developed tuberculosis of wrist near about 2 years after she was on conventional DMARDS for RA. Her tuberculosis of wrist joint was initially missed. She was managed conservatively and concurrently with DMARDS and anti-tubercular drugs for both the diseases. At 3 years follow up, both diseases are under control with painless functional range of motion of the wrist despite presence of radiological gross bony destruction.

Keywords: Tuberculosis, wrist joint, Rheumatoid Arthritis, DMARDS.

Introduction

The risk of infection remains a significant issue for the treatment of rheumatoid arthritis in developing countries because of the immunosuppression associated with the use of glucocorticoids and most DMARDS. In some developing countries, patients undergoing treatment of RA have a substantial increase in the incidence of tuberculosis.⁽¹⁾

Case Summary

A 26 year old lady with bilateral symmetrical multiple joint pain and swelling with morning stiffness was diagnosed as rheumatoid arthritis and has been on conventional DMARDS under the supervision of a medicine specialist since Sept 2012. She was started on weekly oral methotrexate 15 mg & folic acid 5mg and daily deflazacort 6mg & hydroxychloroquine 300 mg. Deflazacort was tapered and then stopped by the end of 3 months. The rest of the DMARDS were continued as before. She was on regular follow up with investigations of blood count, RBS, LFT and KFT. Her symptoms were under control.

In Oct 2014, she developed increase in pain, swelling and painfully restricted movement of her left wrist. But such aggravation of symptoms did not affect her other peripheral joints. A few weeks later, she developed two discharging sinuses proximal to the wrist joint- one on dorsal and other on ventral surface. There were no systemic symptoms. She consulted her physician for these complaints. The abnormalities in her investigations revealed increase in ESR (80mmAEFH), Neutrophils in DLC (81%) and CRP (123.7mg/L). Anemia, diabetes mellitus, haemoglobinopathies, hypoalbuminemia, hepatic and kidney disease and HIV infections were ruled out. Culture from wound for micro-organism was negative.

She was given linezolid iv for two weeks followed by oral for one week at a dose of 600mg twice daily. In the meantime, DMARDS were continued. Symptoms of her left wrist decreased, discharge from sinuses reduced and sinuses seemed to heal following linezolid therapy. But 3-4weeks after stoppage of linezolid therapy, symptoms including sinuses and discharge reappeared.

At this stage, she on her own consulted a dermatologist for her reappeared sinuses and discharge. The dermatologist did x-ray of the left wrist with hand in AP and lateral view (Fig. 1a, 1b) and biopsy (Fig. 2) from the sinus tract under local anesthesia. Histopathological examination revealed it as a tuberculoma.

On being referred by the dermatologist, she presented to us. The X-ray of left wrist with hand revealed irregular destruction of distal end of left radius, some carpal bones and proximal ends of some of the metatarsals. (Fig. 1a, 1b) Montoux test was positive. Chest x-ray was normal.

Antitubercular drugs were started under our institutional protocol of DOTS (Directly Observed Treatment Short course) regimen under category I (newly diagnosed extra-pulmonary TB) under RNTCP (Revised National Tuberculosis Control Programme). She was given 4 drugs of isoniazid (300mg), rifampicin (450mg), pyrazinamide (1500mg) and ethambutol (1200mg) at 3 days a week dose for 2 months of Intensive Phase followed by isoniazid (300mg) and rifampicin (450mg) for another 7 months of continuation Phase. The previous DMARDS regimen was continued. The left wrist was splinted till pain subsided.

Regular checkup was done with monitoring of clinical, radiological and biochemical markers (HB%, blood count, LFT etc.). Symptoms subsided, discharge stopped and sinuses healed in due course of time.

Supervised physiotherapy for range of movement and strengthening exercise was started.

At 3 years of follow up, she is still continuing DMARDs and there is no recurrence of symptoms of either TB wrist or RA. Her peripheral joints including left wrist are painless, have no evidence of active inflammation, (Fig. 3a, 3b) have near normal range of motion (pronation of left forearm restricted in terminal range) and are functionally useful (Fig. 5a, 5b, 6a, 6b) despite the presence of gross bony destructions on x-ray of the left wrist and hand. (Fig. 4a, 4b)

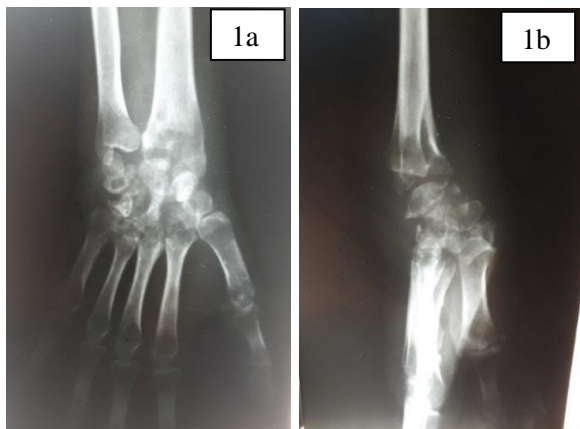

Fig. 1a, b: X-ray showing active tubercular arthritis of wrist

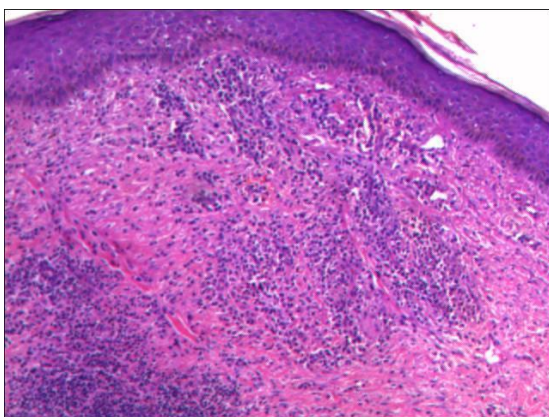


Fig. 2: Showing-microscopic picture of tuberculoma from biopsy specimen

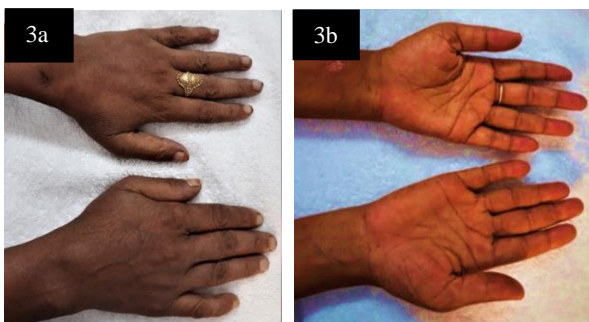

Fig. 3a, b: Showing- healed sinuses on dorsal and ventral surface of wrist joint

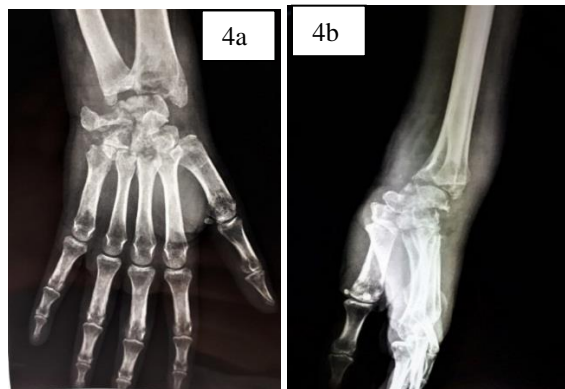


Fig. 4a, b: Showing- X-ray of healed tuberculosis of wrist



Fig. 5a, b: Showing- at 3 years follow up, active supination and pronation of wrist



Fig. 6a, b: Showing- at 3 years follow up, active dorsiflexion and palmar flexion of wrist

Discussion

Skeletal tuberculosis affects 1-3% of all tuberculosis patients. Wrist joint is rarely affected.⁽²⁾ It is well recognized that in some developing countries, patients undergoing treatment of RA have a substantial increase in the incidence of tuberculosis.⁽¹⁾ But incidence of specific association of skeletal tuberculosis in RA patient is not mentioned in the literature.

The increased risk of infection, especially opportunistic fungal infections and reactivation of latent

tuberculosis is a major concern for use of biologicals in RA patient for which patients are screened for latent tuberculosis prior to starting the biological.⁽¹⁾ Corticosteroids, amongst the conventional DMARDS, cause susceptibility to infection with all types of pathogenic organisms and may flare up latent tuberculosis. But methotrexate and hydroxychloroquine are not known to cause such susceptibility.⁽³⁾

Our patient never had biological. Corticosteroid was stopped about 20 months prior to tubercular infection in wrist. She was only on methotrexate and hydroxychloroquine when tuberculosis of left wrist occurred. Such occurrence of skeletal tuberculosis infection in RA patients on conventional DMARDS which are not known to cause susceptibility or flare up of latent TB as happened in our case is not commonly described in the literature.

Linezolid, primarily a bacteriostatic drug, is active against Mycobacterium Tuberculosis besides other gram positive organisms.⁽³⁾ Therefore, the signs and symptoms in our patient subsided for about 3-4 weeks when she received IV and oral linezolid for about 3 weeks giving a false impression of disease control.

Ideally diagnosis of tuberculous infection should be confirmed by demonstration of tubercle bacilli in the skeletal tuberculous lesion. However, various authors (Grange et al, Martin et. al, Moon et al) have reported that this has not been possible in all the cases in any series probably because skeletal tuberculosis is a paucibacillary disease. The load of mycobacterium in skeletal TB is less than 10^5 as against 10^7 to 10^9 in pulmonary TB.⁽²⁾ Demonstration of acid fast bacilli by direct smear examination is positive in 10-30% depending on the tissue type whereas cultures are positive in 30-60% of cases. In doubtful cases, it is mandatory to do biopsy and histopathological examination would reveal typical tubercle in untreated cases of shorter duration.⁽²⁾

Despite all these investigations, it is not possible to confirm the exact diagnosis in about 20% of all cases.⁽²⁾ Therefore, Shanmugasundaram et al and Hoffman et al stated that in developing countries, diagnosis of skeletal tuberculosis can be reliably made on clinical and radiological examination.⁽²⁾

The treatment of TB wrist is chemotherapy and splintage of the wrist in 10-15 degrees of dorsiflexion and forearm in mid-prone position. Hodgson et al and Leung et al stated that with effective anti-tubercular drugs and application of sound splintage, surgical intervention is rarely indicated.⁽²⁾

The anti-tubercular drugs and DMARDS were concurrently used in our case. These drugs are known to cause some common side effects. One of the major side effects is dose related hepatotoxicity caused by Isoniazid, rifampicin, pyrazinamide and methotrexate.⁽³⁾ Therefore patient on these drugs concurrently are suggested for liver function tests on periodic basis. Ocular complications like corneal opacity, retinal

damage, loss of visual acuity or color vision, field defect etc. are major common complications of both ethambutol and hydroxychloroquine. The patient on these drugs, therefore need to have periodic ophthalmological checkup.

Pyrazinamide is known to cause arthralgia as a side effect. But whether it aggravates or reactivates such symptoms when used in a RA patient is not mentioned in the literature. Rifampicin is a microsomal enzyme inducer and thus enhances its own metabolism as well as metabolism of some other drugs thus leading to their failure.⁽³⁾ But it is not documented whether rifampicin has such interaction with DMARDS or not.

In patients of tuberculosis of wrist joint treated with anti-tubercular drugs and functional movements, two-thirds would heal with good painless functional range of movements and one-third would heal with gross ankylosis in functional position.⁽²⁾ Our case also has good painless functional range of motion despite the presence of radiological gross bony destruction.

References

1. Ankoor Shah, E. William St. Clair, Rheumatoid Arthritis, Harrison's Principles of Internal Medicine, 18th Edition, vol2, 2749,2751.
2. S M Tuli, tuberculosis of skeletal system, 3rd edition, 4, 20, 31, 36-37,153,156-157.
3. K D Triparthi, Essentials of Medical Pharmacology, 7th edition, 210-211,293,758,767-769.