

Osteoid osteoma of the femur masquerading radiculopathic disease - A case report

Pranav Kothiyal^{1,*}, Puneet Gupta², Kunal Vij³, Ankur Thakur⁴

¹Senior Resident, ²Professor & HOD, ³Assistant Professor, ⁴Junior Resident, Dept. of Orthopaedics, SGRRIMHS, Dehradun, Uttarakhand

***Corresponding Author:**

Email: kothiyalpranav@gmail.com

Abstract

Osteoid osteoma is a benign bony tumour that is common in males and can mimic a variety of regional musculoskeletal painful conditions often leading to a delay in diagnosis if a watchful eye is not kept. It classically causes night pains relieved on taking oral analgesics. Here we present a case report of a female patient who had a osteoid osteoma but was being treated as a case of radiculopathic pain for the past one and a half years.

Keywords: Osteoid osteoma, Radiculopathy

Introduction

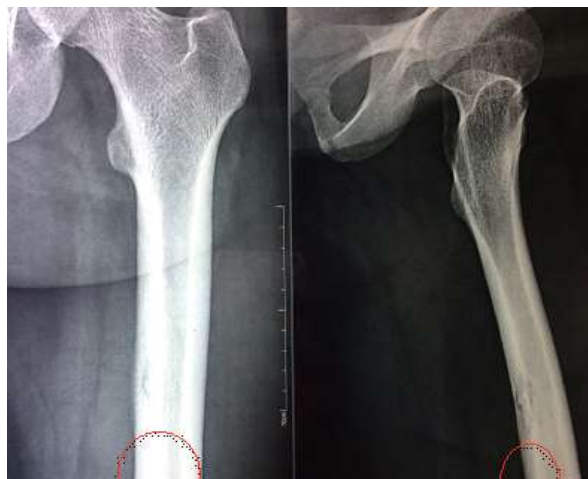Osteoid osteoma was first described by Jaffe and Moyer in 1935. This benign neoplastic bony lesion occurs commonly in second and third decades of life in peripheral long bones of the body like femur and tibia. They consist of a highly vascularised central nidus with a surrounding sclerotic zone. It is usually self limiting but causes severe pain disproportionate to its small size. These tumour can be easily diagnosed nowadays with the current sophisticated imaging methods but can often evade diagnosis when they are concurrently present with neurological symptoms.

Case Report

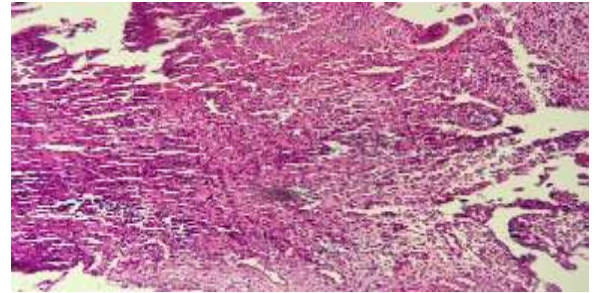
A 24 years female patient came to our side in the OPD complaining of pain in the left thigh since past 2 years. The patient described the pain as vaguely arising in the upper part of the thigh, being predominantly located in the mid thigh and radiating to the knee. The patient had been taking treatment at private hospitals and clinics on and off where she had been investigated by radiological investigations like X-rays and MRI of the lumbosacral spine and diagnosed as a case of disc prolapse with radiculopathy of the left side. The patient gave history of taking medications which were prescribed by various doctors and mainly consisted of analgesics which gave her relief in the pain for one or two days. On examination of the patient she had mild pain in the lower back region without any neurological deficits. The local examination of the left thigh was insignificant except for deep tenderness over the junction of mid and distal third anteriorly. Passive SLR test, Lasegue's, and Bragard's test were negative which made us suspicious of the pain being of a neurological origin so a full length X-ray of the left thigh was done. The X-ray showed sclerosis, mild periosteal thickening and cortical irregularity in the posteromedial diaphysis of femoral shaft. A MRI of the left thigh was done and it showed focal area of hyperintensity with central dot sign. There was cortical erosion and irregularity with

periosteal reaction and adjacent soft tissue inflammation. A CT scan done for localisation of the lesion showed mild sclerotic reaction in the posteromedial cortex of mid shaft having a central dense lesion and surrounding lucency measuring 2.8x0.8x0.8 cm. These findings strongly suggested a diagnosis of osteoid osteoma with acute inflammatory periosteal reaction and soft tissue inflammation. The patient was planned for excisional biopsy and curettage of the lesion. Incision was given medially over the mid thigh and the lesion was identified by the surrounding cortical irregularity. The lesion was excised and sent for histopathological examination and the cavity was curetted and filled with bone graft. The histopathological examination showed bony trabecular lined by osteoblasts. Nidus surrounded by fragmented bony tissue was seen along with lymphoplasmacytic inflammation confirming the diagnosis of osteoid osteoma.

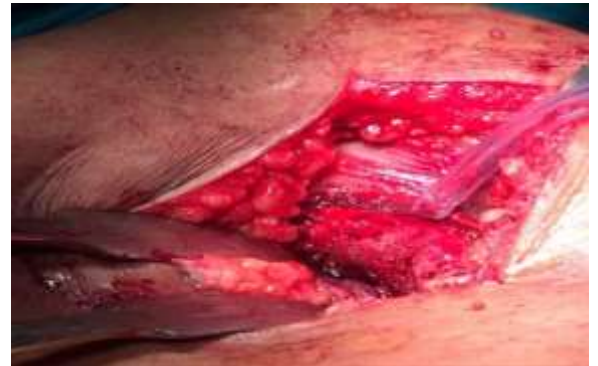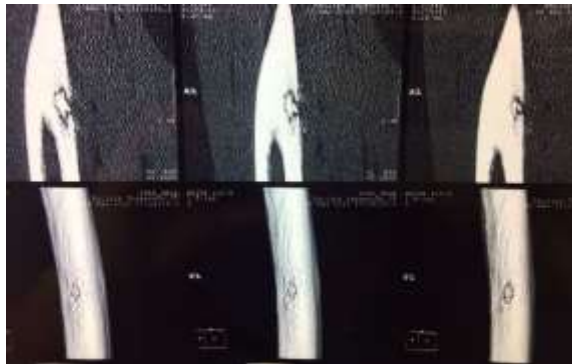Six months postoperatively on follow up there was complete relief of pain and radiological examination did not show presence of any new lesions.



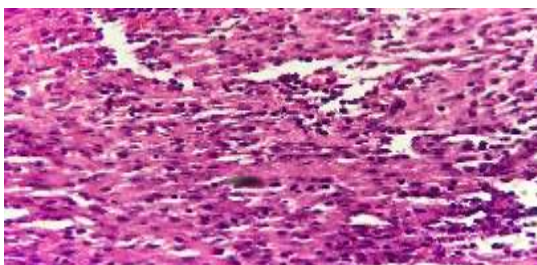
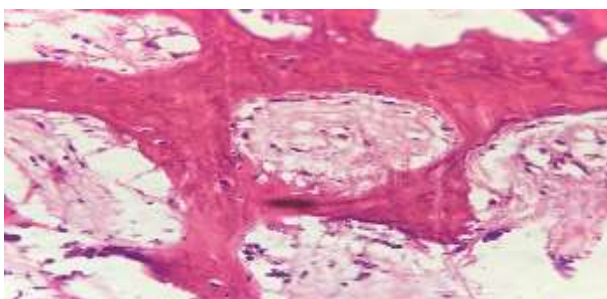
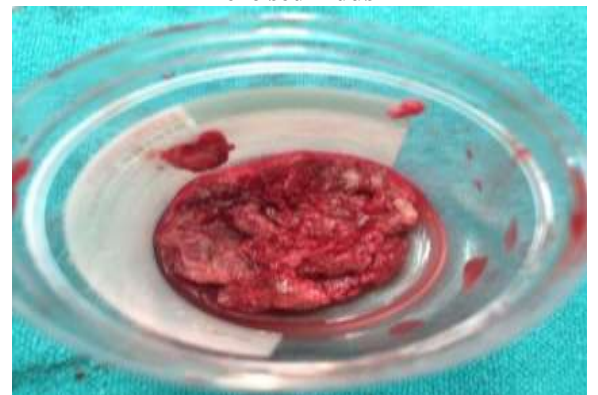
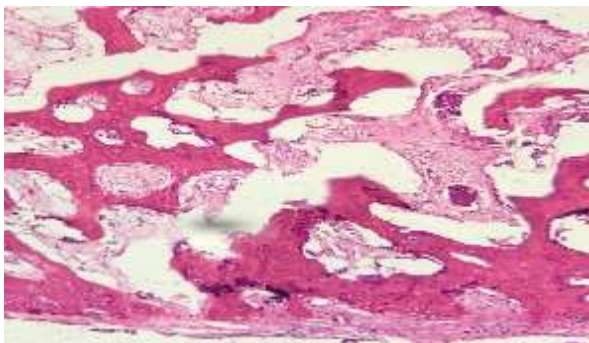
X-ray showing nidus with surrounding radiolucency



Histopathological picture of the excised nidus



Intraoperatively cortical irregularity seen over posteromedial aspect of femoral shaft and the excised nidus



Discussion

Osteoid osteoma is a benign bony neoplasm affecting young adults. It occurs more commonly in the second or third decade of life with a predilection for the male sex. Predisposing factors for this lesions are not very well known but trauma is considered to be a contributing although no direct correlation has been found.⁽¹⁾ Our patient was a female in her early twenties without any predisposing factors.

Other conditions mimicking osteoid osteoma have the one symptom in common with this disease which is pain but the cause and presentation differs markedly and can be easily distinguished if a watchful eye is kept. The cause of pain in osteoid osteoma has been found to be the elevated levels of COX and prostaglandin coenzymes in the nidus and presence of unmyelinated nerve endings is

proximity of the arterial supply of the nidus.^(2,3) The pain is classically aggravated at night time and is relieved dramatically on taking NSAIDs unlike neurological pain or pain due to other articular disorders. Our patient on carefully inquiring gave a detailed history of night pains and how it got magically relieved on taking painkillers which also became a hurdle in early diagnosis. She got accustomed to taking regular NSAIDs and so never sought treatment from a specialist but only physicians who kept on giving her symptomatic treatment for a long time.

Patients of osteoid osteoma can have a varied clinical presentation. Sometimes the diagnosis can be fairly easy with the history, clinical and radiological examination all pointing towards a sureshot diagnosis but many a times patients with concurrent other medical or orthopaedics disorders can make the diagnosis difficult. Not very frequently but once in a while we can come across a patient with this disorder having a long standing history. In such patients there could be muscle atrophy, weakness and diminished deep tendon reflexes. The pain due to the bony lesion and surrounding soft tissue inflammation more often than not can mimic a pain of radiculopathic origin.^(4,5)

Due to lack of awareness, late appearance of characteristic radiological signs and atypical clinical features there is a delay in the diagnosis and the average duration of this delay is more than one year.^(6,7) With longstanding disease inflammatory joint disease, complex regional pain syndromes or features mimicking sacroilitis or osteoarthritis may arise. The diagnosis of our patient was also missed and she had a similar history of being treated for many non-specific causes for a long time. Thus such patients with localised pain having a long history which cannot be accurately diagnosed definitely merit proper radiological investigations on the lines of a osteoid osteoma.

References

1. Ambrosia JM, Wold LE, Amadio PC: Osteoid osteoma of the hand and wrist. *J Hand Surg [Am]*. 1987;12:794-800.
2. Mungo DV, Zhang X, O'Keefe RJ, Rosier RN, Puzas JE, Swarz EM. COX-1 and COX-2 expression in osteoid osteomas. *J Orthop Res* 2002;20:159-62.
3. Schulman L, Dorfman HD. Nerve fibers in osteoid osteoma. *J Bone Joint Surg Am* 1970;52:1351-6.
4. Hsich GE, Davis RG, Darras BT. Osteoid osteoma presenting with focal neurologic signs *Pediatr Neurol* 2002;26(2):148-52.
5. Kiers L, Shield LK, Cole WG. Neurological manifestations of osteoid osteoma. *Arch Dis Child* 1990;65:851-855.
6. Davison WR. Osteoid osteoma: report of atypical cases. *Clin Orthop*. 1956;7:113e123.
7. Ciftdemir M, Tuncel SA, Usta U. Atypical osteoid osteomas. *Eur J Orthop Surg Traumatol*. 2015;25:17e27.