



Case Report

Giant cell tumour of tendon sheath (GCTTS) – 2nd Most common tumour of hand after ganglion cyst

Ozair Khan¹, Tahir Husain², Naman Kandpal^{1*}, V.A Senthil Kumar¹, B. S. Murthy¹, Amit Dhond³

¹Dept. of Orthopaedics, Dharamshila Narayana Superspeciality Hospital, New Delhi, India

²Max Hospiatl, New Delhi, India

³Shatabdi Hospital Kandivali, Mumbai, Maharashtra, India



ARTICLE INFO

Article history:

Received 30-11-2023

Accepted 01-01-2024

Available online 13-02-2024

Keywords:

Giant Cell Tumour of Tendon Sheath (GCTTS)
interphalangeal joint
multinucleated giant cells

ABSTRACT

Probably one of the most common benign neoplasm in the human hand, the Giant Cell Tumour of Tendon Sheath (GCTTS) has been studied by many authors over the years as a popular tumour. There have been studies on the etiological factors, however, limited attention has been given to etiology, prognostic factors, and recurrence rate. Because there are several factors that predispose to recurrence, it is imperative that medical practitioners ensure complete excision of the tumour, including removal of residual satellite nodules. This study is a focus on 0.5cm swelling over dorsal part of the interphalangeal joint of middle finger of the right hand of a 55-year old female that was initially unilobulated, which eventually increased to 3cm and was bilobed over 6 months. With meticulous dissection and the use of magnification loupe to obtain a low recurrence rate, thereby emphasising the key role of surgery as the first prognostic factor of GCTTS.

This is an Open Access (OA) journal, and articles are distributed under the terms of the [Creative Commons Attribution-NonCommercial-ShareAlike 4.0 License](https://creativecommons.org/licenses/by-nc-sa/4.0/), which allows others to remix, tweak, and build upon the work non-commercially, as long as appropriate credit is given and the new creations are licensed under the identical terms.

For reprints contact: reprint@ipinnovative.com

1. Introduction

The Giant Cell Tumour Of The Tendon Sheath (GCTTS) stands as the predominant benign neoplasm in the hand, second only to the ganglion cyst.^{1,2} This tumour is primarily observed in individuals aged 30 to 50 years, and exhibits a higher incidence in women compared to men.^{3–6} Significant cases, up to 45% reported by studies,⁷ have been observed to show local recurrence even after excision. Currently, a standardised treatment protocol is lacking, and the preferred approach remains local excision, with or without adjunct radiotherapy.^{1,2,7–13} Etiological considerations surrounding these tumours have generated multiple hypotheses; however, consensus on etiology, prognostic factors, and recurrence rates remains elusive. To

mitigate recurrence risks, surgeons ensure comprehensive tumour excision, addressing any residual satellite nodules. While marginal excision is the preferred treatment, its execution is often challenging because of several factors; these include the location of the tumour and its firm adhesion to the tendons or neurovascular bundles.

2. Case Report

In this context, the study is on a 55-year-old female who had an insignificant swelling initially, which was unilobulated of about 0.5 cm over dorsal aspect of interphalangeal joint of middle finger of right hand, but gradually increased to 3 cm and became bilobed over the period of 6 months. Because of this swelling, the patient had trouble in fine movement, especially performing daily chores and her daily routine was affected. No history or similar swelling was identified in the

* Corresponding author.

E-mail address: khanozair93@gmail.com (N. Kandpal).

rest of the body including family history that was related to the swelling.

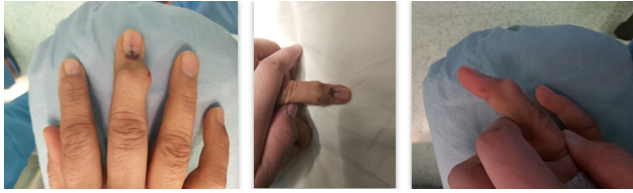


Figure 1: Initial observation of the GCTTS

Based on the initial observation, the patient was investigated through X-ray and MRI

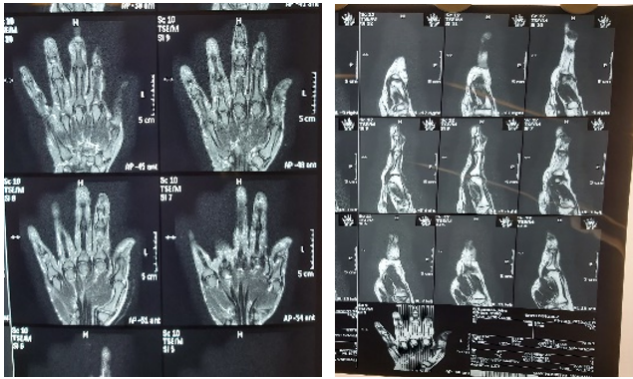


Figure 2: Investigation from MRI scans

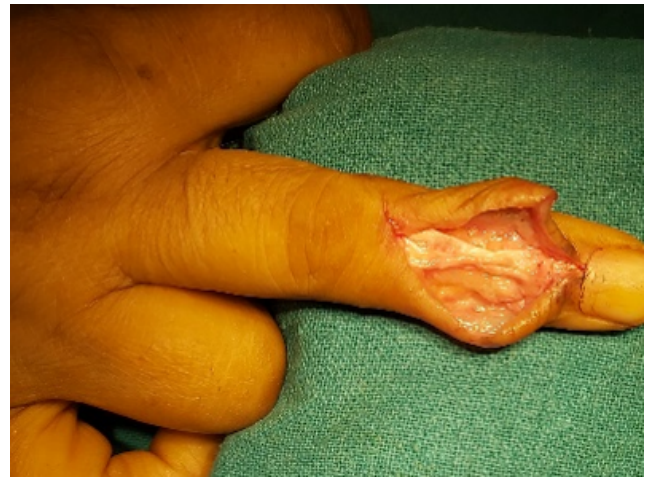

Figure 4: After excision of tumour

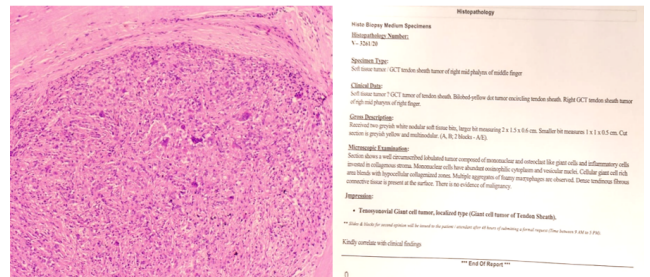


Figure 5: Histopathology slide with its report

On regular diagnosis and investigation from scans, the patient was operated under tourniquet control using a magnifying loupe. Using special care, the tumour was excised completely but capsule was retained with margin of normal tissue.

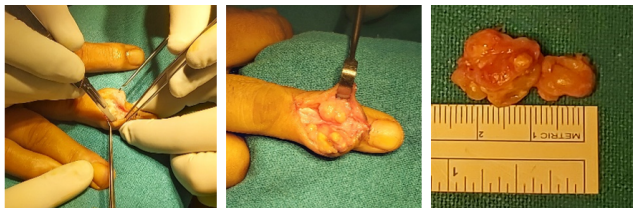

Figure 3: Intra-op images

Any presence of satellite lesions were removed during the operating field. Follow up range was from 2 to 12 months and histopathological diagnosis and immunohistochemical studies were conducted. The Department of Pathology conducted the diagnosis and the results are discussed in the latter part of this study.

2.1. Histopathology slide with reports

The slide showed that GCTTS was composed of multinucleated giant cells, histiocytes polyhedral, fibrotic

material and hemosiderin deposits.

3. Discussion

Several studies in the past have noted that GCTTS is primarily composed of multinucleated giant cells, histiocytes polyhedral, fibrotic material and hemosiderin deposits,^{12,14,15} which is apparent from the slide above. Also, the cellularity and mitosis do not seem to affect the prognosis of cancer, as is identified in some studies.^{5,9,16} One of the first studies on GCTTS was conducted by Jaffe¹⁷ in 1941, explaining it to be a tenosynovitis, a nonneoplastic reaction. This is supported by studies from Vogrincic et al.¹⁸ in 1997, explaining that there is presence of polyclonal cells in lesion; they utilized a polymerase chain reaction based assay for methylation of the X-linked human gene to detect it.

On the contrary, there is a debate from cytogenetic studies that suggest otherwise; according to it, simple structural and numeric aberrations, as well as a variety of balanced chromosomal aberrations are discovered.¹⁹ In particular, clonal structural aberrations affecting the 1p11 to 1p13 region²⁰ and trisomies²¹ of chromosomes 5 and 7 were commonly found. Using fluorescent in situ hybridization probes, Nilsson et al.^{19,20} detected

recurrent breakpoints localized to 1p13, often partnered with 2q35. They advocated the need for activation of a growth promoting gene through balanced translocation for pathogenic mechanism. As there are similar translocations found in haemorrhagic and rheumatoid synovitis, it is doubtful that a neoplastic origin still exists.³

Macrophage Colony Stimulating Factor (CSF1) is a cytokine and hematopoietic growth factor with a crucial role in the proliferation, differentiation, and survival of monocytes, macrophages, and some similar cells. Positioned at the 1p13 breakpoint, it emerges as a key player in the oncogenesis of GCTTS.²² A study conducted in the Stanford University employed several molecular techniques to identify elevated levels of the CSF1 Receptor (CSFR1) in the majority of GCTTS cells, advocating a potential autocrine mechanism that drives neoplastic cell activity.²² Drawing from their study and other research, it can be concluded that GCTTS is indeed a neoplasm.¹⁹ Interestingly, neoplastic cells constitute a minor fraction within the tumour, which constitutes to about a maximum of 16% of the total cells, but greater than 2%. The predominant cellular composition comprises non-neoplastic inflammatory cells recruited and activated by CSF1 produced by the neoplastic cells, a phenomenon termed ‘tumour landscaping’.¹⁹ The sparse distribution of neoplastic cells may explain their elusive detection in the X-linked human androgen receptor gene clonality assay as identified by Vogrinic et al.^{18,23}

Studies from Cupp et al.²³ in 2007 reported a subset of cells exhibiting high CSF1 expression without the presence of 1p13 translocation. They concluded that there is an alternative mechanism in certain tumours (23). Notably, CSFR1, a group II receptor tyrosine kinase sharing structural homology with KIT, raises the possibility of employing a tyrosine kinase receptor inhibitor, such as Imatinib, for the treatment of GCTTS.²⁴

Even though there is a dearth of studies conducted on etiology, there is a vast expanse of literature available that discusses the clinical features and diagnostic approaches of GCTTS. Fotidias et al. (2011) reported a higher prevalence of giant cell tumours of the tendon sheath in women, with a male-to-female ratio of 1:1.47 and occurring mostly in the age group of 30 to 50 years.²⁵ Several studies^{2,7,9,10,12} conducted a comprehensive research on the fingers that were most frequently affected, noting that the index finger is the most affected location (29.7%), followed by the thumb (12.9%), the middle finger (24.6%), the third finger (16.8%), and little finger (16%).^{2,7,9,10,12} For most patients, there was painless swelling (84.3%),^{2,7-9,12} and sensory disturbances of the digits are recorded in 4.57% of cases.^{1,2,7-9,12} The average duration of symptoms spans from 6 to 30 months, with a range of 1 to 120 months.^{1,2,7-13} Notably, about 5% of patients have exhibited soft tissue trauma initially.^{1,2,7-13}

An effective way of discerning the nature of a tumour is Sonography as it helps in distinguishing between solid and cystic components, thereby identifying the presence of satellite lesions, while also detailing the lesion’s relationship with surrounding structures.²⁶ Additionally, sonography also provides information about the extent of contact with the underlying tendon and the percentage of circumferential involvement.²⁶ Byers^{9,10} classified GCTTS into two types, that is, the localised nodular type, commonly found in the hand, and the diffuse type, which is more prevalent in joints. Al-Qattan⁹ introduced a novel classification for GCTTS, categorising Type-I as a single, round or multilobulated tumour, and Type-II as the presence of two or more distinct tumours not joined.

In terms of recurrence, there is a considerable statistical heterogeneity with studies reporting an average recurrence rate of 14.8% amongst patients.^{2,7-13,27} Several factors that lead to recurrence include pressure erosion that is visible on radiographs, the tumour’s location at the interphalangeal joint, the presence of degenerative joint disease, and incomplete excision. Reilly et al.⁸ in 1999 and Grover et al.²⁷ in 1998 observed in X-rays that bone erosion contributes to recurrence of such tumours. However, Kitagawa¹¹ contested this in 2004, asserting that bone involvement was a result of simple erosion caused by the tumour’s pressure effect and not true invasion. In addition, Lowyck²⁸ also identified no significant correlation between recurrence and pressure erosions in 2008, explaining that degenerative joint disease or the location at the distal interphalangeal joint does not result in recurrence.

Several authors^{8,9,27} have linked the site of the tumour its recurrence. For instance, Reilly et al. (8) noted a significantly higher recurrence of giant cell tumours at the thumb interphalangeal (IP) joint and digital distal interphalangeal (DIP) joints. This observation may be attributed to the inherent challenge of achieving thorough excision distally at the IP and DIP joint levels, where neurovascular structures closely abut tumor margins, and the surrounding soft tissue envelope is less than ideal.^{2,9,11} A study by Williams et al.¹³ in 2010 identified the high-risk group as those with tumour involvement of the extensor tendon, flexor tendon, or joint capsule.

Authors^{10,25,27} have noted that Type-II tumours have been linked to a higher recurrence rate compared to Type-I giant cell tumours, possibly due to undetected satellite lesions and subsequent incomplete excision, challenging their classification as true recurrences. The lower recurrence rate in prospective studies might reflect the surgeon’s meticulous efforts to identify tumour margins and achieve optimal outcomes. Additionally, these prospective studies may lack sufficient follow-up duration to accurately depict the true recurrence value.

Research has shown that that utilisation of magnifying glasses or a microscope is essential during mass resection,

however, with a lower recurrence rate, as demonstrated by Ikeda,¹⁰ who reported only one recurrence amongst 18 patients with Giant Cell Tumor of the Tendon Sheath (GCTTS) after microscopic excision of the lesion.¹⁰

A study by Kotwal et al.⁹ recommended postoperative radiotherapy with a dose of 20 Gy in divided daily doses of 2 Gy. These are for cases that involve incomplete excision and the presence of mitotic figures,⁹ with some cases of bone involvement in the tumour.⁷ Following this protocol, a study²⁵ observed a recurrence rate of 0% (0 out of 14 patients) while Ng²⁹ in 2010 proposed the use of Fine Needle Aspiration Cytology (FNAC) as a primary diagnostic aid, contributing to preoperative planning and recurrence prevention of the tumours.

4. Conclusion

This study has explained the concept of GCTTS using a case study on surgical exposure, which involved meticulous dissection and use of magnification loupe to obtain a low recurrence rate. It underlined the role of surgery as the first prognostic factor of GCTTS. However, there is a need for more comprehensive research involving a large number of cases to adequately determine the requisite protocol for this tumour.

5. Source of Funding

None.

6. Conflicts of Interest

None.

References

- Darwish FM, Haddad WH. Giant cell tumour of tendon sheath: experience with 52 cases. *Singapore Med J*. 2008;49(11):879–82.
- Uriburu IJ, Levy VD. Intraosseous growth of giant cell tumors of the tendon sheath (localized nodular tenosynovitis) of the digits: report of 15 cases. *J Hand Surg Am*. 1998;23(4):732–6.
- Suresh SS, Zaki H. Giant cell tumour of tendon sheath: case series and review of literature. *J Hand Microsurg*. 2010;2(2):67–71.
- Garg B, Kotwal PP. Giant cell tumour of the tendon sheath of the hand. *J Orthop Surg*. 2011;19(2):218–20.
- Monaghan H, Salter DM, Al-Nafussi A. Giant cell tumour of tendon sheath (localized nodular tenosynovitis): clinicopathological features of 71 cases. *J Clin Pathol*. 2001;54(5):404–7.
- Adams EL, Yoder EM, Kasdan ML. Giant cell tumour of the tendon sheath: experience with 65 cases. *Eplasty*. 2012;12:e50.
- Kotwal PP, Gupta V, Malhotra R. Giant-cell tumour of the tendon sheath. Is radiotherapy indicated to prevent recurrence after surgery? *J Bone Joint Surg*. 2000;82(4):571–3.
- Reilly KE, Stern PJ, Dale JA. Recurrent giant cell tumours of the tendon sheath. *J Hand Surg Am*. 1999;24(6):1298–302.
- Al-Qattan M. Giant cell tumours of tendon sheath: classification and recurrence rate. *J Hand Surg Br*. 2001;26(1):72–5.
- Ikeda K, Osamura N, Tomita K. Giant cell tumour in the tendon sheath of the hand: importance of the type of lesion. *Scand J Plast Reconstr Surg Hand Surg*. 2007;41(3):138–42.
- Kitagawa Y, Ito H, Yokoyama M, Maeda S. The effect of cellular proliferative activity on recurrence and local tumour extent of localized giant cell tumour of tendon sheath. *J Hand Surg Br*. 2004;29(6):604–7.
- Ozalp T, Yercan H, Kurt C. Giant cell tumour of tendon sheath of the hand. *Acta Orthop Traumatol Turc*. 2004;38:120–4.
- Williams J, Hodari A, Janevski P, Siddiqui A. Recurrence of giant cell tumours in the hand: a prospective study. *J Hand Surg Am*. 2010;35(3):451–6.
- Messoudi A, Fnini S, Labsaili N, Ghrib S, Rafai M, Largab A, et al. Giant cell tumors of the tendon sheath of the hand: 32 cases. *Chir Main*. 2007;26(3):165–9.
- Liu PT. Radiological reasoning: acutely painful swollen finger. *AJR Am J Roentgenol*. 2007;188(3 Suppl):13–7.
- Rodrigues C, Desai S, Chinoy R. Giant cell tumour of the tendon sheath: a retrospective study of 28 cases. *J Surg Oncol*. 1998;68(2):100–3.
- Jaffe H, Lichtenstein L, Sutro CJ. Pigmented villonodular synovitis, bursitis and tenosynovitis. *Arch Pathol*. 1941;31:731–65.
- Vogrincic GS, O'Connell JX, Gilks CB. Giant cell tumour of tendon sheath is a polyclonal cellular proliferation. *Hum Pathol*. 1997;28(7):815–9.
- David R, Tenosynovial L. Tenosynovial giant cell tumor: case report and review. *Arch Pathol Lab Med*. 2012;136(8):901–6.
- Nilsson M, Höglund M, Panagopoulos I. Molecular cytogenetic mapping of recurrent chromosomal breakpoints in tenosynovial giant cell tumours. *Virchows Arch*. 2002;441(5):475–80.
- Fletcher JA, Henkle C, Atkins L, Rosenberg AE, Morton CC. Trisomy 5 and trisomy 7 are nonrandom aberrations in pigmented villonodular synovitis: confirmation of trisomy 7 in uncultured cells. *Genes Chromosomes Cancer*. 1992;4(3):264–6.
- West RB, Rubin BP, Miller MA, Subramanian S, Kaygusuz G, Montgomery K, et al. A landscape effect in tenosynovial giant-cell tumor from activation of CSF1 expression by a translocation in a minority of tumor cells. *Proc Natl Acad Sci U S A*. 2006;103(3):690–5.
- Cupp JS, Miller MA, Montgomery KD, Nielsen TO, O'Connell JX, Huntsman D, et al. Translocation and expression of CSF1 in pigmented villonodular synovitis, tenosynovial giant cell tumour, rheumatoid arthritis and other reactive synovitides. *Am J Surg Pathol*. 2007;31(6):970–6.
- Cassier PA, Gelderblom H, Stacchiotti S, Thomas D, Maki RG, Kroep JR, et al. Efficacy of imatinib mesylate for the treatment of locally advanced and/or metastatic tenosynovial giant cell tumour/pigmented villonodular synovitis. *Cancer*. 2012;118(6):1649–55.
- Fotidias E, Papadopoulos A, Svarnas T, Akritopoulos P, Sachinis NP, Chalidis BE, et al. Giant cell tumour of tendon sheath of the digits. A systematic review. *Am Ass Hand Surg*. 2011;6(3):244–9.
- Middleton WD, Patel V, Teeffey SA, Boyer MI. Giant cell tumours of the tendon sheath: an analysis of sonographic findings. *AJR Am J Roentgenol*. 2004;183(2):337–9.
- Grover R, Grobbelaar AO, Richman PI, Smith PJ. Measurement of invasive potential provides an accurate prognostic marker for giant cell tumour of tendon sheath. *J Hand Surg Br*. 1998;23(6):728–31.
- Lowyck H, Smet LD. Recurrence rate of giant cell tumours of the tendon sheath. *Eur J Plast Surg*. 2006;28:385–8. doi:10.1007/s00238-005-0791-6.
- Ng VY, Thomas K, Crist M. Fine needle aspiration for clinical triage of extremity soft tissue masses. *Clin Orthop Rel Res*. 2010;468(4):1120–8.

Author biography

Ozair Khan, Senior Resident

Tahir Husain, Junior Consultant

Naman Kandpal, Clinic Associate  <https://orcid.org/0009-0000-3691-8516>

V.A Senthil Kumar, HOD

B. S. Murthy, Director Orthopaedics

Amit Dhond, HOD

Cite this article: Khan O, Husain T, Kandpal N, Kumar VAS, Murthy BS, Dhond A. Giant cell tumour of tendon sheath (GCTTS) – 2nd Most common tumour of hand after ganglion cyst. *IP Int J Orthop Rheumatol* 2023;9(2):103-107.