

Content available at: <https://www.ipinnovative.com/open-access-journals>

IP International Journal of Orthopaedic Rheumatology

Journal homepage: www.ijor.org

Original Research Article

Treatment of osteoarthritis knee with bone marrow aspirate concentrate injection

Chinmoy Das¹, Partha Pratim Das¹, Navonil Gupta¹, Somesh Saha^{1*}¹Dept. of Orthopaedics, Tezpur Medical College and Hospital, Tezpur, Assam, India

ARTICLE INFO

Article history:

Received 28-10-2023

Accepted 29-11-2023

Available online 13-02-2024

Keywords:

BMAC intraarticular injection

NPS

OKS

ABSTRACT

Aim: To assess the clinical effectiveness and safety of bone marrow aspirate concentrate (BMAC) injections given intraarticularly as a potential treatment for knee osteoarthritis (OA).

Materials and Methods: Data from 60 patients with knee osteoarthritis treated with BMAC injection at a single centre between December 2021 and December 2022 were retrospectively examined. We only included patients with idiopathic osteoarthritis. Post-traumatic osteoarthritis, prior knee surgery, ageless than 50 years or over 85 years, an active infection, uncontrolled diabetes mellitus, rheumatological or another systemic condition, cancer, or immunosuppressive medication use were all exclusion factors.

A single-spin manual approach was used to aspirate and concentrate bone marrow from the iliac crest. The Numeric pain scale (NPS) and Oxford knee score (OKS) were used to evaluate patients both before and after the treatment. A 12-month follow-up period was used.

Results: The statistical analysis comprised a total of 60 patients. With a mean age of 67 years (range 50-85), there were 42 females and 18 males. At the end of the follow-up period, the mean NPS reduced from 8.12 to 4.31 ($p < 0.001$) and the mean OKS rise from 22.30 to 34.74 ($p < 0.001$). There were no problems.

Conclusion: A single BMAC intra-articular injection is a dependable and safe technique that improves the clinical condition of knee OA.

This is an Open Access (OA) journal, and articles are distributed under the terms of the [Creative Commons Attribution-NonCommercial-ShareAlike 4.0 License](https://creativecommons.org/licenses/by-nc-sa/4.0/), which allows others to remix, tweak, and build upon the work non-commercially, as long as appropriate credit is given and the new creations are licensed under the identical terms.

For reprints contact: reprint@ipinnovative.com

1. Introduction

The deterioration and loss of articular cartilage associated with synovitis, subchondral bone remodelling, and osteophyte production characterize osteoarthritis (OA), a chronic progressive degenerative condition.^{1,2} With pain, stiffness, and severe functional restrictions, it is one of the main causes of disability.³ OA is typically a result of articular cartilage "wear and tear," but changes associated with it are biochemically mediated,⁴ through an imbalance between intra-articular anabolic and catabolic cytokines.⁵ It has significant socioeconomic implications^{6,7} and a significant financial burden on the economy.⁸ As a result, the joint eventually develops mechanical and biological

dysfunction,⁹ along with cartilage loss and synovial inflammation, due to the poor self-renewal and avascular nature of the articular cartilage.¹⁰ Early-stage degenerative arthritis treatments primarily aim to reduce inflammation and discomfort,¹¹ but they have no impact on the disease's course.¹²

The natural course of the disease cannot be changed by conservative treatments such as non-steroidal anti-inflammatory drugs (NSAIDs) and steroids, as well as glucosamine, chondroitin sulphate, omega-3 fatty acids, and intra-articular visco supplementation.^{13,14} Visco supplementation is typically only effective in the early stages of osteoarthritis, and the pain relief it provides is only brief.^{15,16} In contrast, corticosteroid injections relieve symptoms temporarily but come with the danger of exacerbating cartilage degeneration and causing tissue

* Corresponding author.

E-mail address: sahasomesh84@gmail.com (S. Saha).

atrophy.¹⁷

When all other forms of treatment have failed, total knee arthroplasty (TKA) is subsequently performed.¹⁸ Research has been focused on the creation of therapy techniques to give a symptomatic improvement by influencing joint homeostasis in response to the recent surge in interest in the field of regenerative medicine.¹⁹ The most recent innovation is the extraction of mesenchymal stem cells (MSCs) from autologous bone marrow Aspirate Concentrate (BMAC), followed by concentration for patients with cartilage disease of injectable intra-articular orthobiologic therapy.^{20,21} MSCs are multipotent cells having the ability to differentiate into chondrocytes, adipocytes, and osteoclasts as well as exhibit great capacities for self-renewal. The most reliable and practical source of MSCs is BMAC. Intra-articular administration has led to tissue regeneration, improved function, and pain relief. BMAC is created by centrifuging bone marrow aspirate (BMA), which is commonly taken from the iliac crest, through a density gradient. Hematopoietic stem cells (HSCs), MSCs, platelets, chemokines, and cytokines like PDGF and TGF- β have been demonstrated to be abundant in BMAC. These growth factors (GFs) can trigger MSC chondrogenesis and are not only present in the alpha granules of platelets,²² but they are also released by MSCs. Moreover BMAC possesses in general, anti-inflammatory, angiogenic trophic and immunomodulatory properties that can potentially have anabolic and anti-inflammatory effects enhancing cartilage repair.^{23,24}

2. Materials and Methods

Type of study-Hospital based prospective study

Place of study-Tezpur medical college and hospital

Duration of study- 1 year

Patients selection

2.1. Inclusion criteria

All patients attending orthopaedics OPD and casualty at Tezpur medical college with

1. Idiopathic OA (Kellgren Lawrence grade III and IV).
2. Age more than 50 years less than 85 years.
3. Patients ready for 1 year follow up.

Exclusion criteria

1. History of infection, trauma, or tumours of the knee joint.
2. Concurrent knee instability requiring surgical treatments, such as ligament reconstruction.
3. Concurrent knee malalignment requiring surgical treatments.
4. Inflammatory arthritis, such as rheumatoid arthritis and ankylosing spondylitis.

5. <1-year follow-up.
6. Abnormal muscle activity or ambulatory difficulties.
7. Patients not giving consent.

Sample size

Patients underwent BMAC injections between December 2021 to December 2022.

2.2. Procedure

The iliac crest was marked with the patient lying on the operation table. Surgically prepared and draped. Conscious sedation and local anaesthetic (1% lidocaine) were used together. Prior to aspiration, a jamshidi needle and six 10ml-syringes are flushed with heparin (5000 U/20ml) and then filled with 1 ml heparin solution.

The jamshidi needle is introduced and progressed through the incision using a stab motion the anterior superior iliac spine's periosteum. Once the periosteum has been punctured.

The stylet and driver are taken out, and a 10ml syringe with 1ml of heparin is inserted. 8 ml of bone marrow are aspirated using syringe [Figure 1].

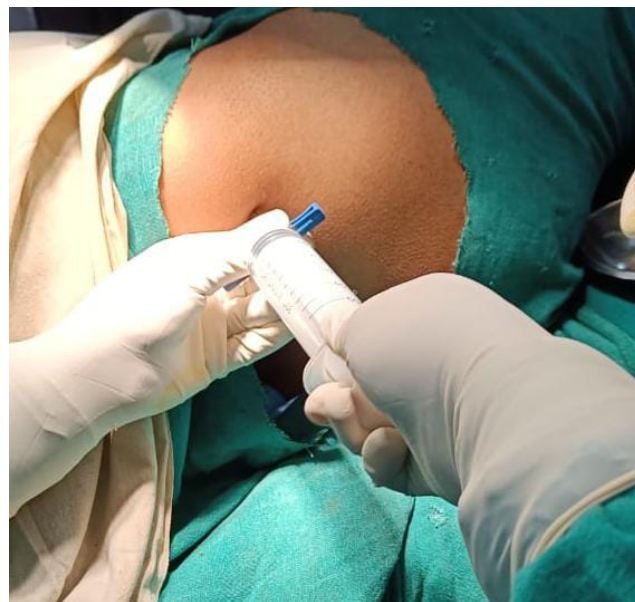

Figure 1:

Extra attention was paid to keeping the needle stationary throughout the process. Contrary to previous authors' recommendations, the needle was neither moved or twisted after each subsequent 10 mL aspiration in order to lessen peripheral blood contamination (hemodilution). For the treatment of one knee, a total of 60 ml of bone marrow was extracted (BMA). After aspirating the bone marrow, the jamshidi needle is removed, pressure is applied to the skin entrance site, and then a dressing is provided. After extraction, the aspirate is put into sterile tubes and

carefully processed by hand in a separate space under sterile conditions in order to remove the buffy coat using centrifugation [Figure 2].

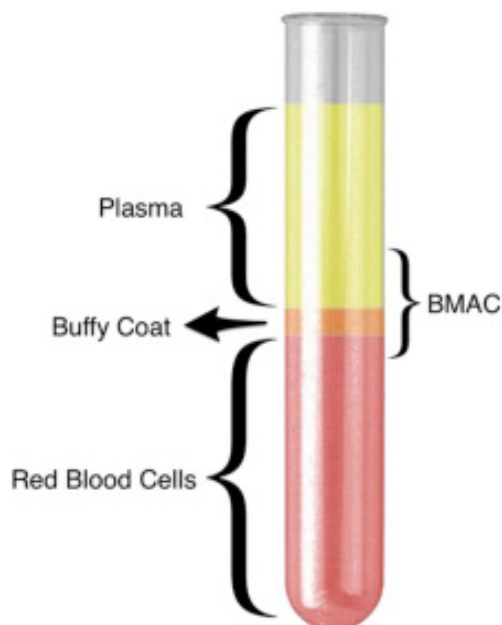


Figure 2:

For every 60 ml of BMA, a single-spin centrifuge produced 15 ml of BMAC, which was then brought back to the operating room and administered as 10 ml of BMAC injections into knee joint under sterile settings. The 60 ml aspirate's supernatant portion was saved and additionally used as prolotherapy at the joint line level. To avoid any possible interactions with the BMAC, all injections were carried out by the same doctor without anaesthesia using an anterolateral approach to the knee joint. The knee joint was passively moved throughout its range of motion immediately after injection to evenly distribute the fluid.

Full weight bearing was permitted for the patients, who were also told to resume light activity as tolerated while avoiding oral NSAIDs and corticosteroids for at least four weeks after the procedure. Patients were permitted to resume their full schedule of activities after six weeks.

No additional treatment measures (such as bracing or physical therapy) were taken.

2.3. Outcome measurement

The outcome was evaluated using a validated Oxford knee score (OKS) questionnaire for functional evaluation and a numeric Pain Scale (NPS) (0 to 10) for pain intensity (NPS has eleven levels of pain ranging from 0 for no pain to 10 for the worst possible pain). The knee joint-specific self-administered questionnaire known as the OKS was created. There are 12 questions on the questionnaire, and a total score of 48 indicates maximum function.

Evaluations were conducted by phone calls and direct patient evaluations in varied time frames (mean follow-up time: 9 months) before the delivery of treatment and post-procedure. The patients were questioned about their satisfaction with the treatment and if they would recommend it to others during the last follow-up.

2.4. Stastical analysis

The Paired t test was used to compare the pre- and post-treatment results. Statistics were considered significant for probability (p) values under 0.05.

3. Results

The study included 60 patients (60 knees) based on the inclusion and exclusion criteria. There were 36 right knees and 24 left knees (Chart 2). With a mean age of 67 years that ranged from 50 to 85 years. There were 18 (30%) males and 42 (70%) females. (Chart 1) Standing anteroposterior (AP) view was used to determine the severity of the degenerative arthritis; there were 24 (40%) instances of grade III and 36 (60%) cases of grade IV (Chart 3). At the last check-up, the mean NPS dropped from 8.12 preoperative to 4.31 postoperative (p 0.001) (last follow-up). Additionally, the mean OKS increased from 22.30 prior to surgery to 34.74 following surgery (p 0.001). A total of 3 patients (5%) chose to go with complete knee replacement, 41 patients (68.33%) said they would repeat the treatment, 45 patients (75%) indicated that they would recommend the procedure to a friend.

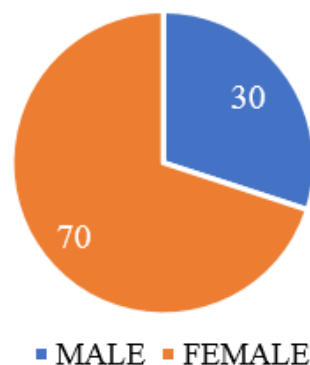


Chart 1: Sex distribution

The results are summarized in Table 1.

Recurrence of knee pain was not further documented in the study group, and this would be the focus of a follow-up examination in the future. The relationship between age, OA grade, and declining scores was unrelated. There were no side effects, such as paresthesias, hematomas, or harvest-related pain.

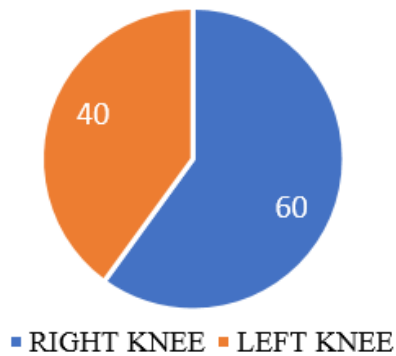


Chart 2: Knee distribution

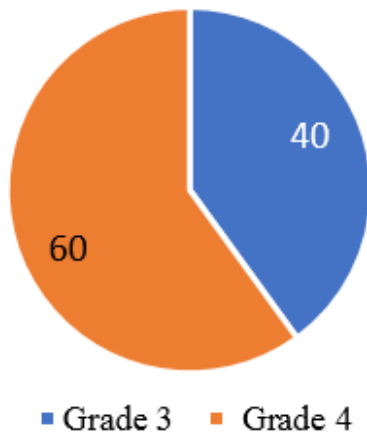


Chart 3: Severity distribution

Table 1: Summary of Results (60 patients)

Measuring scale	Pre treatment	Post treatment	P value
NPS	8.12	4.31	<0.001
OKS	22.30	34.74	<0.001

NPS- Numeric pain score
OKS-Oxford knee score

4. Discussion

Trauma and orthopaedic surgery have shown a great deal of interest in MSCs due to their ability to differentiate into the desired cell lineage to make chondrocytes, adipocytes, and osteocytes²⁵ and their propensity for self-renewal. The BMAC process is technically simple and quick, allowing the harvesting and intraoperative transplantation to be completed in a single session.²⁶ BMAC may be the safest and most practical source of MSCs for bone tissue regeneration. Hematopoietic stem cells, platelets, growth factors (GFs), cytokines, and chemokines are also present in BMAC.²⁷

The feasibility, safety, and effectiveness of bone marrow-derived MSC treatment in treating knee OA are currently being supported by a large number of published research.²⁸

With regard to patients with grade 4 arthritis, specific human trials revealed improvements in range of motion, pain scores, functional status of the knee, and walking distance, a shortened hospital stay, and the creation of cartilage and bone regeneration.

In this study, we retrospectively monitor 60 osteoarthritis patients who received a single intra-articular injection of BMAC and describe the clinical outcomes. In the vast majority of patients, the operation was well tolerated and improved pain and function during both short- and long-term follow-up.

In contrast to our methodology, a previous study by Centeno et al.²⁹ using 424 knees of 373 individuals with knee osteoarthritis and BMAC injections supported the idea that the final MSC number is crucial for the best results.

Sampson et al.,³⁰ who treated 73 patients with osteoarthritis of the knee (73 knees) with a single intra-articular injection of BMAC and a single platelet-rich plasma injection at eight weeks, came to the conclusion that this combination is effective in treating moderate to severe osteoarthritis in the short term.

25 individuals with bilateral knee osteoarthritis participated in a double-blind, randomized control trial that was undertaken by Shapiro et al.³¹ BMAC was injected into one side, whereas 0.9% normal saline was put into the side across from it. At six months, there was no statistically significant difference in how well the patient could operate. However, it is impossible to say for sure that the MSCs injected did not contribute to relieving the symptoms in the opposite knee given that MSCs supplied to any site have the capacity to move to areas of inflammation.

There are a few restrictions on this study. First, the absence of a control group should be considered when interpreting the data. Second, because the study was retrospective, it was unable to collect data at the predetermined intervals, therefore case-by-case follow-up was required. Thirdly, because the study's participants have advanced (grades 3 and 4) knee osteoarthritis, the results of treatment on individuals with less severe conditions were not examined.

5. Conclusion

MSCs are a viable therapy option for knee OA. This study demonstrated that a single intra-articular injection of BMAC appeared to produce long-term effects despite the aforementioned limitations. In addition to avoiding the need for hospitalization, the operation is quick, easy, well tolerated, and produces no problems or negative side effects. To further understand the function of BMAC therapy, as well as to establish the ideal dose, administration method, and frequency of treatment, more research is required.

6. Authors' Contributions

Prof Dr. Chinmoy Das has made substantial contributions to the concept and design, and is the main author. Dr. Partha pratim Das, Dr. Navonil Gupta and Dr. Somesh Saha have been involved in the drafting of the manuscript and revised it critically for important intellectual content. All authors have agreed to be accountable for all aspects of the work. Dr. Somesh Saha is the corresponding author. All authors read and approved the final manuscript.

7. Ethical Approval

The study was approved by the Institutional Ethics Committee.

8. Source of Funding

No funding sources.

9. Conflict of Interest

None declared.

Acknowledgements


The authors would like to thank the patients, departmental staff, and Tezpur Medical College and Hospital administration.

References


- Goldring MB, Goldring SR. Articular cartilage and subchondral bone in the pathogenesis of osteoarthritis. *Ann N Y Acad Sci.* 2010;1192:230–7. doi:10.1111/j.1749-6632.2009.05240.x.
- Ishiguro N, Kojima T, Poole AR. Mechanism of cartilage destruction in osteoarthritis. *Nagoya J Med Sci.* 2002;65(3-4):73–84.
- Neogi T. The epidemiology and impact of pain in osteoarthritis. *Osteoarthritis Cartilage.* 2013;21(9):1145–53.
- Lee AS, Ellman MB, Yan D, Kroin JS, Cole BJ, van Wijnen A, et al. A current review of molecular mechanisms regarding osteoarthritis and pain. *Gene.* 2013;527(2):440–7.
- Kapoor M, Martel-Pelletier J, Lajeunesse D, Pelletier JP, Fahmi H. Role of proinflammatory cytokines in the pathophysiology of osteoarthritis. *Nat Rev Rheumatol.* 2011;7(1):33–42.
- Guccione AA, Felson DT, Anderson JJ, Zhang Y, Wilson PW, Kelly-Hayes M, et al. The effects of specific medical conditions on the functional limitations of elders in the Framingham study. *Am J Public Health.* 1994;84(3):351–8.
- Johnson VL, Hunter DJ. The epidemiology of osteoarthritis. *Best Pract Res Clin Rheumatol.* 2014;28(1):5–15.
- Bitton R. The economic burden of osteoarthritis. *Am J Manag Care.* 2009;15(8 Suppl):230–5.
- Baltzer AW, Ostapczuk MS, Stosch D, Seidel F, Granrath M. A new treatment for hip osteoarthritis: clinical evidence for the efficacy of autologous conditioned serum. *Orthop Rev.* 2013;5(2):59–64.
- Zheng D, Dan Y, Yang SH, Liu G, Shao Z, Yang C, et al. Controlled chondrogenesis from adipose derived stem cells by recombinant transforming growth factor-beta3 fusion protein in peptide scaffolds. *Acta Biomater.* 2015;11:191–203. doi:10.1016/j.actbio.2014.09.030.
- Kon E, Filardo G, Roffi A, Andriolo L, Marcacci M. New trends for knee cartilage regeneration: from cell-free scaffolds to mesenchymal stem cells. *Curr Rev Musculoskelet Med.* 2012;5(3):236–43.
- and LSS. Osteoarthritis. *Curr Rheumatol Rep.* 1999;1:45–7.
- Mcalindon TE, Bannuru RR, Sullivan MC, Arden NK, Berenbaum F, Bierma-Zeinstra M, et al. OARSI guidelines for the non-surgical management of knee osteoarthritis. *Osteoarthritis Cartilage.* 2014;22(3):363–88.
- Benke M, Shaffer B. Viscosupplementation treatment of arthritis pain. *Curr Pain Headache Rep.* 2009;13(6):440–6.
- Jevsevar D, Donnelly P, Brown GA, Cummins DS. Viscosupplementation for Osteoarthritis of the Knee: A Systematic Review of the Evidence. *J Bone Joint Surg Am.* 2015;97(24):2047–60.
- Bellamy N, Campbell J, Robinson V, Gee T, Bourne R, Wells G, et al. Intraarticular corticosteroid for treatment of osteoarthritis of the knee. *Cochrane Database Syst Rev.* 2006;(2):5328. doi:10.1002/14651858.CD005328.
- Kim JD, Lee GW, Jung GH, Kim CK, Kim T, Park JH, et al. Clinical outcome of autologous bone marrow aspirates concentrate (BMAC) injection in degenerative arthritis of the knee. *Eur J Orthop Surg Traumatol.* 2014;24(8):1505–11.
- Anz AW, Hackel JG, Nilssen EC, Andrews JR. Application of biologics in the treatment of the rotator cuff, meniscus, cartilage, and osteoarthritis. *J Am Acad Orthop Surg.* 2014;22(2):68–79.
- Koelling S, Miosge N. Stem cell therapy for cartilage regeneration in osteoarthritis. *Expet Opin Biol Ther.* 2009;9(11):1399–405.
- Szychlińska MA, Stoddart MJ, Amora U, Ambrosio L, Alini M, Musumeci G, et al. Mesenchymal stem cell-based cartilage regeneration approach and cell senescence: can we manipulate cell aging and function? *Tissue Eng Part B Rev.* 2017;23(6):529–39.
- Belmont PJ, Goodman GP, Waterman BR, Bader JO, Schoenfeld AJ. Thirty-day postoperative complications and mortality following total knee arthroplasty: incidence and risk factors among a national sample of 15,321 patients. *J Bone Joint Surg Am.* 2014;96(1):20–6.
- Pittenger MF, Mackay AM, Beck SC. Multilineage potential of adult human mesenchymal stem cells. *Science.* 1999;284(5411):143–7.
- Turner LG. Federal Regulatory Oversight of US Clinics Marketing Adipose-Derived Autologous Stem Cell Interventions: Insights From 3 New FDA Draft Guidance Documents. *Mayo Clin Proc.* 2015;90(5):567–71.
- Jager M, Hernigou P, Zilkens C, Herten M, Fischer J, Krauspe R, et al. Cell therapy in bone-healing disorders. *Orthopade.* 2010;39(4):463–62.
- Mccarrel T, Fortier L. Temporal growth factor release from platelet-rich plasma, trehalose lyophilized platelets, and bone marrow aspirate and their effect on tendon and ligament gene expression. *J Orthop Res Off Publ Orthop Res Soc.* 2009;27(8):1033–42.
- Huang AH, Motlekar NA, Stein A, Diamond SL, Shore EM, Mauck RL, et al. High-throughput screening for modulators of mesenchymal stem cell chondrogenesis. *Ann Biomed Eng.* 2008;36:1909–21. doi:10.1007/s10439-008-9562-4.
- Indrawattana N, Chen G, Tadokoro M, Shann LH, Ohgushi H, Tateishi T, et al. Growth factor combination for chondrogenic induction from human mesenchymal stem cell. *Biochem Biophys Res Commun.* 2004;320(3):914–9.
- Sampson S, Botto-Van Bemden A, Aufiero D. Autologous bone marrow concentrate: review and application of a novel intra-articular orthobiologic for cartilage disease. *Phys Sportsmed.* 2013;41(3):7–18.
- Centeno CJ, Al-Sayegh H, Bashir J, Goodyear S, Freeman MD. A dose response analysis of a specific bone marrow concentrate treatment protocol for knee osteoarthritis. *BMC Musculoskel Disord.* 2015;16:258. doi:10.1186/s12891-015-0714-z.
- Sampson S, Smith J, Vincent H, Aufiero D, Zall M, Botto-Van-Bemden A, et al. Intra-articular bone marrow concentrate injection protocol: short-term efficacy in osteoarthritis. *Regen Med.* 2016;11(6):511–20.
- Shapiro SA, Kazmerchak SE, Heckman MG, Zubair AC, Connor MI. A prospective, single-blind, placebo-controlled trial of bone marrow aspirate concentrate for knee osteoarthritis. *Am J Sports Med.* 2016;16:258. doi:10.1186/s12891-015-0714-z.

Author biography

Chinmoy Das, Professor and HOD  <https://orcid.org/0000-0002-2857-7552>

Partha Pratim Das, Assistant Professor  <https://orcid.org/0000-0001-8483-6355>

Navonil Gupta, Senior Registrar  <https://orcid.org/0000-0002-1048-9263>

Somesh Saha, Post Graduate Trainee  <https://orcid.org/0009-0001-6945-7442>

Cite this article: Das C, Das PP, Gupta N, Saha S. Treatment of osteoarthritis knee with bone marrow aspirate concentrate injection. *IP Int J Orthop Rheumatol* 2023;9(2):68-73.