

Synovial chondromatosis of the hip - A Case Report

Pranav Kothiyal^{1,*}, Gyaneshwar Tank², Amit Gupta³

¹Senior Resident, ²Associate Professor, ³Lecturer, L.L.R.M. Medical College, Uttar Pradesh

***Corresponding Author:**

Email: kothiyalpranav@gmail.com

Abstract

Background: Synovial chondromatosis is a benign, relatively rare condition arising from synovial membrane of joints. It usually affects middle aged individuals arising in large joints. The treatment is surgical by removal of the loose bodies and hyperactive synovium. This case report documents this rare synovial pathology in the hip joint and its management by open synovectomy and loose body excision.

Case Report: A thirty one year old female presented with the complaint of insidiously increasing swelling in the right groin with pain and progressively increasing restriction of movements at right hip. After clinical and radiological examination the patient was diagnosed as stage three synovial chondromatosis of hip and was managed by open synovectomy with loose body excision. The histopathology of the excised specimens confirmed the diagnosis.

Conclusion: Surgical management is most often required in patients with symptomatic and progressive disease as in this case. Loose body excision and complete synovectomy offers reliable cure in young patients where replacement arthroplasty can be considered later on.

Keywords: Hip joint, Synovium, Chondromatosis, Arthritis, Synovectomy

Introduction

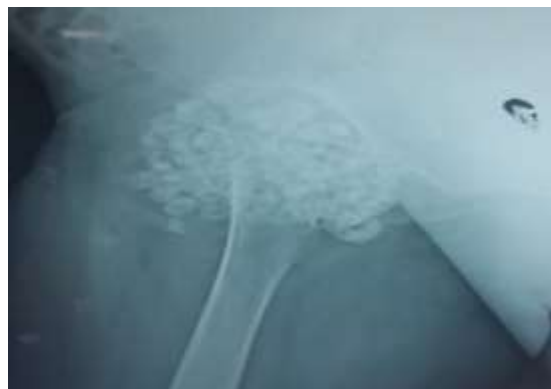Synovial Chondromatosis is a rare benign pathological condition that affects synovial membranes.

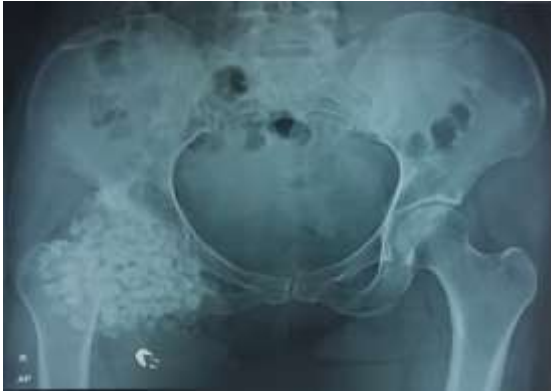It mostly involves large synovial joints like knee hip and elbow. It is characterized by formation of cartilage with synovial metaplasia. The diagnosis is made by clinical and radiological examination.

Case Report

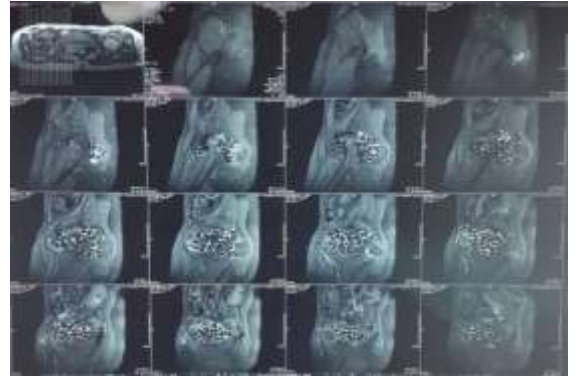
A 31 year old woman presented with the complaint of pain in the right hip region since past two years which gradually increased in intensity over time. The pain was localized to the hip region and was aggravated when the patient was bearing weight on the right lower limb or walking. About 6 months ago the patient noticed a swelling in the inguinal region appreciated more prominently over the anterior aspect. The swelling progressively increased in size over past six months. The patient gradually developed difficulty in walking and squatting on the floor. There was no history of any injury to the hip region, any history of fever or significant weight loss or loss of appetite. On examination the range of movements was reduced in all planes. Active flexion of 70 degree with a further passive flexion of 10 degree, 25 degree of abduction and 10 degree of adduction was present. All the movements were globally painful and were associated with palpable crepitations on the inguinal region. There was an active SLR of 60 degrees and passive SLR of 70 degrees and no fixed deformity at the hip. Plain X-ray films with both hip joints and pelvis in the AP and LAT view showed soft tissue swelling around the neck of femur and multiple oval shaped calcified structures of a uniform oval size around femoral head and neck. MRI showed effusion of the right hip joint with multiple pellet

like small filling defects which were indicative of synovial chondromatosis. Open synovectomy of the hip joint was done by posterior approach and as much synovium as possible with the calcified nodules were removed. Hundreds of pellets ranging in size from 1 to 2 cm were removed along with the thickened capsule. The pellets were round or oval in shape with smooth shiny surface. The synovium and the loose bodies were sent for histopathological examination. The histopathological examination confirmed the clinico-radiological diagnosis. Postoperatively the patient was advised physiotherapy of the hip by mobilization and strengthening exercises. The range of movements in all the planes improved but was slightly painful due to early arthritis of the hip secondary to long standing disease for which the patient sought treatment quite late. There was no recurrence till now that is one year after surgery.

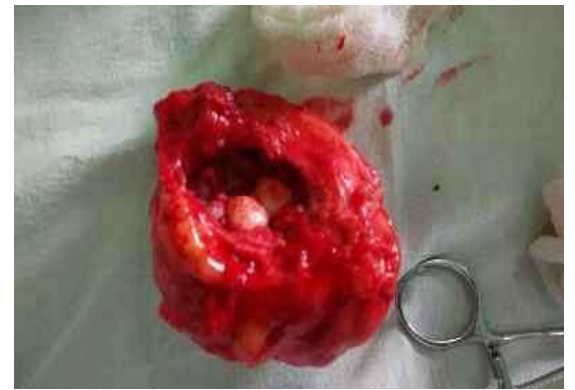
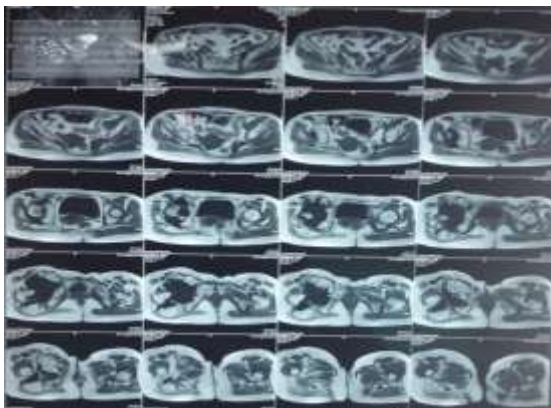
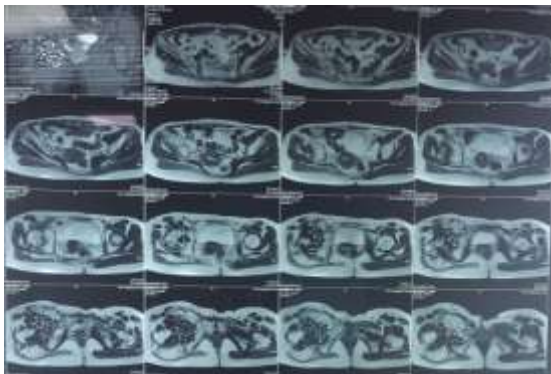
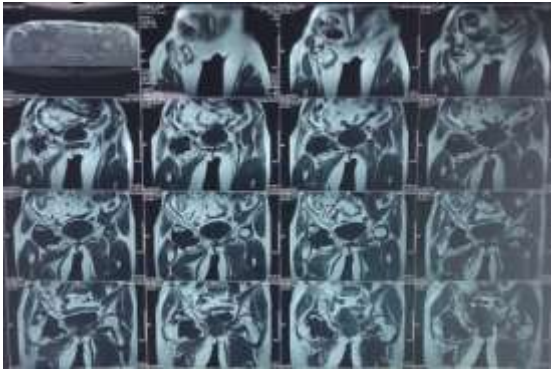




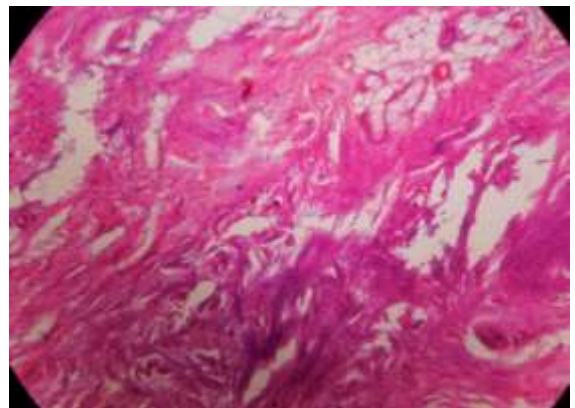
AP and LAT x-ray views of the right hip joint



AXIAL and SAGGITAL sections of the joint on MRI

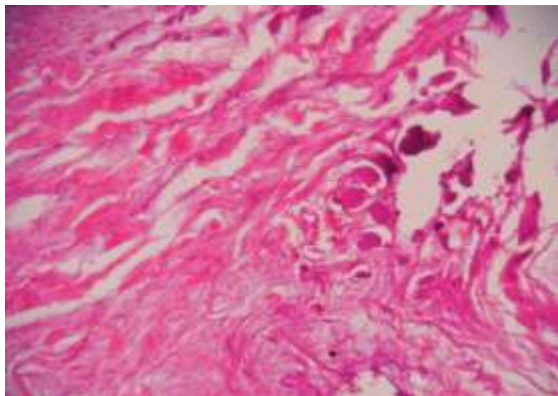


Histopathological view of the specimens showing cartilage formations



Thickened synovium that was excised





Round marble like pellets

Discussion

Synovial Chondromatosis is a rare condition with an unknown aetiology. It is characterized by formation cartilaginous bodies in the synovium and in the connective tissues of the large joints.^{1,2} The pathological process of the disease involves three stages. The first stage is characterized by synovitis, there are no loose bodies yet formed. The second stage is characterized by formation of loose in the joint but they are still cartilaginous. The third stage involves calcification of the cartilaginous bodies and the synovial hyperactivity subsides. With the progression of disease the loose bodies get ossified and are visible radiologically on X-rays³. This condition is mostly seen as a monoarticular condition and more than 50% cases are reported to be in the knee joint.⁴ In our case the involvement was seen in the hip joint which is the second most commonly involved joint. Synovial Chondromatosis usually presents in third to fifth decade of life, rarely seen in children and has a sex predilection occurring twice more commonly in males^{5,6}. Our patient was in the third decade but was a female contrary to the condition being commoner in males. Synovial chondromatosis is widely differentiated into two types; the primary type and the secondary type. The primary type occurs in a normal joint secondary to cartilaginous metaplasia of synovial cells with trauma as the most common inciting stimulus⁷. Secondary synovial chondromatosis is caused by embedding of cartilage fragments from articular surfaces into the synovium causing a metaplastic change thus producing chondroid nodules⁸. The patients with synovial chondromatosis often present with pain, decreased range of motion at the joint, palpable mass or nodular swelling and locking of joint⁶ most of which were the presenting complaints in our patient. Often the patient may not present with any complaint and the lesion may be an incidental finding. Plain radiographs, ultrasound, CT scan and MRI are diagnostic modalities used but MRI is the modality of choice because it can delineate soft tissues better⁹. The treatment depends on the symptoms and the demands of the patient. Removal of the loose bodies along with synovectomy is usually the treatment of choice in active synovitis¹⁰. It can be

done arthroscopically or by open arthrotomy. Total hip arthroplasty can also be done if synovial chondromatosis co-exists with arthritis. Complications of synovial chondromatosis are secondary osteoarthritis, malignancy, recurrence of disease^{11,12}.

References

1. Hocking R, Negrine J. Primary synovial chondromatosis of the subtalar joint affecting two brothers. *Foot & Ankle International*. 2003;24:865-7.
2. Krebbs VE. The role of hip arthroscopy in the treatment of synovial disorders and loose bodies. *Clin Orthop Rel Resch*. 2003;406:48-59.
3. Miligram JW: Synovial osteochondromatosis. *J Bone Joint Surg* 1977;59-A:792.
4. Iossifidis A, Sutaria PD, Pinto T. Synovial chondromatosis of the ankle. *The Foot*. 1995;5:44-6.
5. Kistler W. Synovial chondromatosis of the knee joint: a rarity during childhood. *Eur J Pediatr Surg* 1991 Aug;1(4):237-9.
6. Valmassy R, Ferguson H. Synovial Osteochondromatosis: A brief review. *J Am Podiatr Med Assoc* 1992;82:427-31.
7. Leu JZ, Matsubara T, Hirohata K. Ultrastructural morphology of early cellular changes in the synovium of primary synovial chondromatosis. *Clin Orthop*. 1992;276:299-306.
8. Peh WCG, Shek TWH, Davies AM, Wong JWK, Chien EP. Osteochondroma and secondary synovial osteochondromatosis. *Skeletal Radiol*. 1999;28:169-74.
9. Frick MA, Wenger DE, Adkins M. MR imaging of synovial disorders of the knee: an update. *Radiol Clin North Am* 2007 Nov;45(6):1017-31.
10. Ogilvie-Harris DJ, Saleh K. Generalized synovial chondromatosis of the knee: A comparison of removal of the loose bodies alone with arthroscopic synovectomy. *Arthroscopy* 1994 Apr;10(2):166-70.
11. Ackerman D, Lett P, Galat DD Jr, Parvizi J, Stuart MJ: Results of total hip and total knee arthroplasties in patients with synovial chondromatosis. *J Arthroplasty* 2008;23(3):395-400.
12. Peter H, Neil A, Justin C, Ali F, William H. Malignant transformation in synovial chondromatosis of the knee? *The Knee* 2001 Oct;8(3):239-42.