

Comparative analysis of functional outcome between commonly available modalities of treatment in Tennis Elbow patients

Vijay Vasant Nemade^{1,*}, Suyog Prakash Burgute², Punarvasu Rajeev Jagtap³, Ganesh Tanaji Mundhe⁴

¹Assistant Professor, ^{2,3,4}PG Student, SKNMC, Pune

***Corresponding Author:**

Email: nemadevijay5@gmail.com

Abstract

Introduction: Tennis Elbow is very common condition and affects approximately 1% to 3% of the population and is more common (affecting 15%) in individuals involved in repeated forceful activities with forearm. Various methods have been advocated for the treatment of Tennis elbow with variable success. The aim of this study was to compare the functional outcome of commonly available modalities of treatment in patients with Tennis elbow.

Methods: 163 Patients diagnosed as Tennis elbow and treated at our institute between July 2013 to February 2015 and those who were followed up in Out Patient Department or on telephone up to February 2016 were retrospectively studied. All patients with a new episode of Tennis elbow were included in the study. Patients with polyarthritis, arthritis of the Elbow, previous fracture of the elbow and patients with neurological condition were excluded. 52 patients were treated with Local Injection of Corticosteroid, 58 patients were treated with Brace and 53 patients were treated with Local Ultrasound Therapy. All Patients were followed as per routine protocol and at each follow up visit functional assessment was done. The end point of the study was 1 year after completion of treatment. Overall success was defined as a 20% difference between treatment groups in the primary outcome measure. We compared groups with χ^2 test.

Results: In all three groups patient characteristics were comparable. At the end of first week of treatment recovery or improvement was reported in 48 patients (92.3%) in the Injection group, 28 patients (48.2%) in the Brace group and 30 patients (56.6%) in the Local Ultrasound group. At second week Injection group was better than in the Local Ultrasound and Brace groups. After four weeks 4 (7.6%) patients in Injection Group complained of recurrence of pain, 11 (21%) patients complained of moderate pain during work and 8 patients complained of mild pain during work. Pain relief and average functional outcome of Local Ultrasound Group was better as compared to other two groups at 4 weeks follow up examination and thereafter till end point of the study.

Conclusions: Our results demonstrated Good Functional outcome in patients treated with Local Ultrasound Therapy and it was sustained over long period of time. Initial results in patients treated with Local Injection of Corticosteroid were better as compared to other modalities of treatment till first 4 weeks of follow up but they were not sustained over further follow up visits till one year.

Keywords: Tennis Elbow, Local Ultrasound Therapy, Injection of Corticosteroid, Brace.

Introduction

Lateral elbow pain without any history of trauma is the most common cause of disability in working individuals and most commonly it is diagnosed as lateral epicondylitis or Tennis Elbow. This is very common condition and affects approximately 1% to 3% of the population.¹⁻⁵ The condition is more common (affecting 15%) in individuals involved in repeated forceful twisting, gripping, lifting heavy weights, throwing, pulling activities or combination of these activities and in those using vibrating tools.²⁻⁷

Various methods have been advocated for the treatment of Tennis elbow. They include rest, non-steroidal anti-inflammatory medication, bracing local ultrasound, Local injection of corticosteroids, Local injection of platelet rich plasma and low-level laser therapy.^{1,5,6} Various types of surgical procedures have also been recommended but they are required very rarely in resistant and recurrent cases. Treatment modalities like Local injection of platelet rich plasma and low-level laser therapy have shown good results but are not available at all centres.^{8,9} Since Tennis Elbow is quite common condition all patients cannot be referred

to higher centres for treatment. Therefore we conducted this retrospective study to compare results of commonly available modalities of treatment and to determine optimal treatment strategy amongst commonly available treatment modalities before referring few resistant cases to higher centres.

Patients and Methods

Patients diagnosed as Tennis elbow and treated at our institute between July 2013 to February 2015 and those who were followed up in Out Patient Department or on telephone up to February 2016 were retrospectively studied. All patients with a new episode of Tennis elbow (pain and tenderness over lateral region of the elbow and no history of similar complaints in past) were included in the study. Patients with polyarthritis, arthritis of the Elbow, previous fracture of the elbow and patients with neurological condition were excluded. The study was approved by the research ethics committees and informed written consent was obtained from all patients. We could trace records of 163 patients who fulfilled our inclusion, exclusion and follow up criteria. Of these patients we

studied, 52 patients were treated with Local Injection of Corticosteroid, 58 patients were treated with Brace and 53 patients were treated with Local Ultrasound Therapy.

Group A: Injection Group—Patients were given a local corticosteroid injection of methylprednisolone 20 mg and 1 ml 2% lignocaine according to a standard technique. The injection was given with the patient's arm kept flexed on a firm surface. The methylprednisolone and lignocaine were drawn in two different sterile disposable syringes. Skin was cleaned and under all aseptic precautions first lignocaine was injected deep into the subcutaneous tissues 1 cm distal to the lateral epicondyle and aiming towards the tender spot. Keeping the needle in place, syringes were then exchanged and methylprednisolone was injected.⁷ Then the needle was withdrawn and firm pressure applied. In addition all these patients received 15 minutes of Ice fomentation for 2 days, 5 days course of oral Non-Steroidal Anti-inflammatory drugs (NSAIDS) and Physical therapy by Physiotherapist in the form of passive exercises initially followed by judicious active and resisted exercises.

Group B: Brace group: These patients were treated with application of Tennis Elbow Brace which is available everywhere. Patients were advised to apply Brace over upper third of forearm for 6 weeks.⁹ In addition all these patients received 15 minutes of Ice fomentation for 2 days, 5 days course of oral NSAIDS and Physical therapy by Physiotherapist in the form of passive exercises initially followed by judicious active and resisted exercises.

Group C: Local ultrasound group: These patients were treated with Local Ultrasound therapy. The ultrasound machine that was used in the study was a standard routine machine commonly used by all physiotherapists.⁷ The machine was standardised initially and then every month thereafter on a master balance. Treatment was given with a frequency of 10 MHz. It was given in contact, using Electro Medical Supplies' ultrasonic coupling medium. Eight settings were given over a period of two weeks. In addition all

these patients received 15 minutes of Ice fomentation for 2 days, 5 days course of oral NSAIDS and Physical therapy by Physiotherapist in the form of passive exercises initially followed by judicious active and resisted exercises.

All Patients were followed as per routine protocol and at each follow up visit functional assessment was done as point system mentioned here:

1. Tenderness over lateral epicondyle(0 = no tenderness, 1= mild tenderness, 2 = moderate tenderness, 3 = severe tenderness)
2. Pain on resisted extension (if painful 1 point, no pain = 0 point)
3. Noting intensity of rest pain on 0 to 10 VAS scale.
4. Noting pain (0-3) induced by daily activities(0 = no pain, 1= mild pain, 2 = moderate pain, 3 = severe pain)
5. Noting pain (0-3) induced during work.

All the above points were aggregated and outcome measured on 20 point scale. Score of 0 to 3 points was considered as satisfactory outcome, 4 to 7 as average outcome and more than 7 as poor outcome. The end point of the study was 1 year after completion of treatment. Those patients who recovered completely and who did not come for follow up visits were asked above questions on telephone. Sample size calculations were based on publications which describe a 70% recovery or improvement. Overall success was defined as a 20% difference between treatment groups in the primary outcome measure. We compared groups with χ^2 test.¹⁰ Area under the curve slopes were compared by the methods of Matthews et al.¹¹ Analyses were carried out with SPSS.

Results

163 patients were retrospectively evaluated of which 52 patients received Local Injection of Corticosteroids, 58 patients received treatment with application of Brace and 53 patients received Local Ultrasound Therapy. In all three groups patient characteristics were comparable.

Table 1: Baseline characteristics of the study sample

Patient characteristics	Group A Local injection of corticosteroids	Group B Brace group	Group C Local ultrasound therapy
Total number of patients	52	58	53
Males	27	23	31
Females	25	35	22
Average Age	40.2 years	39.6 Years	41.8 years
Manual labourers	34	39	34
Moderate work (House wives, Supervisors, shopkeepers, etc.)	17	18	16
Sedentary work	01	01	03

At one weeks, outcome in the Injection group was significantly better than in the Local Ultrasound and Brace groups (Graph 1). Local Ultrasound showed better results over Brace group. At the end of first week of treatment recovery or improvement was reported in 48 patients (92.3%) in the Injection group, 28 patients (48.2%) in the Brace group and 30 patients (56.6%) in the Local Ultrasound group. At second week Injection group was better than in the Local Ultrasound and Brace groups. (Fig. 1) At four weeks 4 (7.6%) patients in Injection Group complained of recurrence of pain, 11 (21%) patients complained of moderate pain during work and 8 patients complained of mild pain during work. Pain relief and average functional outcome of Local Ultrasound Group was better as compared to other two groups at 4 weeks follow up examination and thereafter till end point of the study.

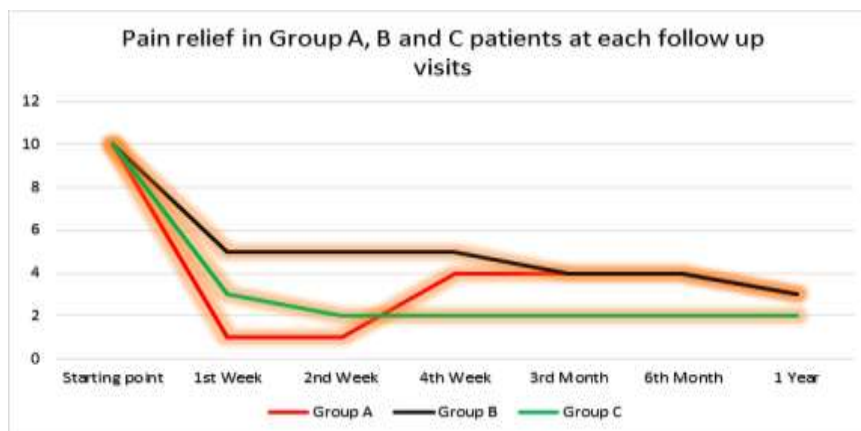


Fig. 1: Pain relief in three different treatment group patients

Table 2: Average scores of functional assessment for the treatment Groups A, B and C

Treatment Groups	Average Functional score at 1 st Week	Average Functional score at 2 nd Week	Average Functional score at 4 th Week	Average Functional score at 3 rd month	Average Functional score at 6 th month	Average Functional score at 1 Year
Group A Local injection of corticosteroids	2	2	4	4	3	3
Group B Brace group	8	8	8	6	4	3
Group C Local ultrasound therapy	5	4	3	2	2	2

47% of patients in Injection Group required an average of 2 additional courses of oral Non-steroidal Anti-inflammatory drugs. 62% of the patients in Brace Group required an average of 3 additional courses of oral Non-steroidal Anti-inflammatory drugs and 2 courses of topical analgesics. Whereas 31% of the patients in Local Ultrasound group required an average of 2 additional courses of oral Non-steroidal Anti-inflammatory drugs.

4 (7.6%) patient in Injection Group experienced recurrence of pain at 4 weeks and they received 2nd Injection.

7 (13.2%) patients required 4 additional sessions of Local ultrasound therapy during follow up visits at 4 weeks and 12 weeks.

Complications such as local skin atrophy and pigmentation at the lateral epicondyle was observed in two patients at six months and one patient at 12 months in Injection Group. Increase in severity of pain immediately after injection was seen in 6 patients who

subsided completely in next 2 days. No complications were noted in patients treated with Local ultrasound therapy and Brace.

Discussion

Individuals involved in performing repeated stressful activities with forearm are at risk of stress injury to the tendons commonly at their site of origin. When this stress injury involves extensor tendons at their origin that leads to development of severe pain at lateral epicondyle of the humerus and this condition is known as Tennis Elbow.¹² Inflammation sets in at injury site leading to severe pain and disability.¹² Therefore Tennis elbow is considered an overload injury or strain of the forearm extensor muscles. This condition has a potential risk of turning into chronic disorder if not treated early after onset. Therefore it is important to treat this condition as early as possible.¹³

Numerous methods such as rest, non-steroidal anti-inflammatory medication, bracing, local ultrasound and

Injection of corticosteroids have been advocated for treating Tennis Elbow patients with variable success rates.¹⁴ Now a days Local injection of PRP (platelet rich plasma) is considered as most successful treatment modality for Tennis Elbow patients. PRP releases growth factors and cytokines. These bioactive proteins stimulate the healing process in stress injury at origin of extensor tendons.^{15,16} But this form of therapy requires advanced equipment which is not available everywhere.

Local injection of corticosteroids shows excellent recovery at 1st week to 4th weeks but recurrence of pain is seen from 1st month to 6th month after therapy. This may occur due to overuse the arm after injection as a result of complete pain relief.^{17,18} Corticosteroids acts by their strong anti-inflammatory action at the local injection site but they never stimulates the healing process. Application of Tennis Elbow Brace gives supports to the forearm tendons and muscles and thus provide pain relief.¹⁹

Various Researchers have found positive effect of Local Ultrasound in the healing process of injured tendons at their origin. Dyson et al, using control groups, showed enhanced tissue regeneration due to Local Ultrasound in an animal model.²⁰ They demonstrated enhanced blood flow, increased membrane permeability, and altered connective tissue extensibility and nerve conduction. Stimulation of protein synthesis with fibroblast activation has also been reported.²¹ All these effects leads to tissue regeneration and repair of injured tendons at their origin resulting in pain relief and functional recovery.¹³ Therefore, amongst various modalities of treatment PRP and Local Ultrasound are shown to stimulate healing process at the stress injury site.

Clinical results in our study shown excellent results in those patients treated with Local injection of Corticosteroid over those treated with Local Ultrasound Therapy and Brace at follow up during 1st week and 2nd week. But after 4 weeks 7.6% of patients in Injection Group experienced recurrence of pain and patients treated with Local Ultrasound Therapy continued to have more pain relief and good functional recovery. Follow up of these patients for 1 year showed a sustained improvement with local ultrasound use in comparison to Local Injection of Corticosteroids and use of Braces. In addition we found low recurrence rate with local ultrasound as compared with those patients treated with Local injection of corticosteroids and use of Braces. 47% and 62% of patients in Injection Group and Brace Group respectively required an average of 2 to 3 additional courses of oral Non-steroidal Anti-inflammatory drugs and 2 courses of topical analgesics as against only 31% of the patients in Local Ultrasound group required an average of 2 additional courses of oral Non-steroidal Anti-inflammatory drugs. Mild complications such as local skin atrophy, pigmentation at the lateral epicondyle and Increase in severity of pain immediately after injection were seen in 17.3% of

patients treated with Local Injection of Corticosteroids. Whereas no complications occurred in patients treated with local ultrasound and Brace. Therefore overall functional outcome was better in patients treated with Local Ultrasound Therapy than in those treated with Local Injection of Corticosteroid and Tennis Elbow Brace.

Conclusions

Our results demonstrated good Functional outcome in patients treated with Local Ultrasound Therapy and it was sustained over long period of time with less number of additional treatments, less recurrences and no complications as against those treated with Local Injection of Corticosteroid and Tennis Elbow Brace.

Limitations

Point system used for functional assessment is not validated. But according to us this is rapid assessment and helps examiner to assess improvement or worsening of patients within 5 minutes correctly by a simple method and with minimal inter-observer variations.

References

1. WalkerBone K, Palmer K, Reading I, Coggon D, Cooper C. Prevalence and impact of musculoskeletal disorders of the upper limb in the general population. *Arthritis Rheum* 2004;51:642-51.
2. Chiang HC, Ko YC, Chen SS, Yu HS, Wu TN, Chang PY. Prevalence of shoulder and upper limb disorders among workers in the fish-processing industry. *Scand J Work Environ Health* 1993;19:126-31.
3. Kurppa K, Viikari JunturaE, Kuosma E, Huuskonen M, Kivi P. Incidence of tenosynovitis or peritendinitis and epicondylitis in a meat-processing factory. *Scand J Work Environ Health* 1991;17:32-7.
4. Ranney D, Wells R, Moore A. Upper limb musculoskeletal disorders in highly repetitive industries: precise anatomical physical findings. *Ergonomics* 1995;38:1408-23.
5. Jobe FW, Ciccotti MG. Lateral and medial epicondylitis of the elbow. *J Am Acad Orthop Surg*. 1994;2(1):1-8.
6. Nirschl RP. Elbow tendinosis/tennis elbow. *Clin Sports Med*. 1992;11(4):851-870.
7. Hong QN, Durand MJ, Loisei P. Treatment of lateral epicondylitis: where is the evidence? *Joint Bone Spine*. 2004;71(5):369-373.
8. Alsousou J, Thompson M, Hulley P, Noble A, Willett K. The biology of platelet rich plasma and its application in trauma and orthopaedic surgery: A review of the literature. *J Bone Joint Surg Br* 2009;91:987-96.
9. Oken O, Kahraman Y, Ayhan F, Campolat S, Yargonciogiu Z. The Short-term Efficacy of Laser, Brace, and Ultrasound Treatment in Lateral Epicondylitis: A Prospective, Randomized, Controlled Trial. *Journal of Hand Therapy*. 2008;28(1):63-68.
10. Stull PA, Jokl P. Comparison of diflusal and naproxen in the treatment of tennis elbow. *Clin Ther* 1986;9:62-66.
11. Matthews JN, Altman DG, Campbell MJ, Royston P. Analysis of serial measurements in medical research. *BMJ* 1990;300:230-235.

12. Molloy T, Wang Y, Murrell G. The roles of growth factors in tendon and ligament healing. *Sports Med* 2003;33:381-94.
13. Dyson M, Pond JB, Joseph J, Warwick R. The stimulation of tissue regeneration by means of ultrasound. *Clin Sci* 1968;35:273-85.
14. Hong QN, Durand MJ, Loisei P. Treatment of lateral epicondylitis: where is the evidence? *Joint Bone Spine*. 2004; 71(5):369-373.
15. Molloy T, Wang Y, Murrell G. The roles of growth factors in tendon and ligament healing. *Sports Med* 2003;33:381-94.
16. Mishra A, Woodall J Jr, Vieira A. Treatment of tendon and muscle using platelet rich plasma. *Clin Sports Med* 2009;28:113- 25.
17. Assendelft WJ, Hay EM, Adshead R, Bouter LM. Corticosteroid injections for lateral epicondylitis: a systematic overview. *Br J Gen Pract*.1996;46(405):209-216.
18. Smidt N, Van der Windt D, Assendelft W, Deville W, Korthals de Bos I, Bouter L. Corticosteroid injections, physiotherapy, or a wait-and-see policy for lateral epicondylitis: a randomised controlled trial. *Lancet* 2002;359:657–62.
19. Kamien M. A rational management of tennis elbow. *Sports Med* 1990;9:173-191.
20. Dyson M, Pond JB, Joseph J, Warwick R. The stimulation of tissue regeneration by means of ultrasound. *Clin Sci* 1968;35:273-85.
21. Binder AI, Hazleman BL. Lateral humeral epicondylitis-a study of natural history and the effect of conservative therapy. *Br_J Rheumatol* 1983;22:73-6.