

Content available at: <https://www.ipinnovative.com/open-access-journals>

IP International Journal of Orthopaedic Rheumatology

Journal homepage: [www.ijor.org](http://www.ijor.org)

## Case Report

# Excellent outcome of a patient with acute back pain and osteoporotic fracture- A case report

Subramanian Nallasivan<sup>1,2,\*</sup>, Raja S Vignesh<sup>3,4</sup>, Arunkumar Govindarajan<sup>5</sup>

<sup>1</sup>Dept. of Rheumatology and Medicine, Rosemary Mission Hospital, Tirunelveli, Tamil Nadu, India

<sup>2</sup>Dept. of Rheumatology and Medicine, Velammal Medical College Hospital, Madurai, Tamil Nadu, India

<sup>3</sup>Dept. of Neurosurgeon, Thoothukkudi Medical College, Thoothukudi, Tamil Nadu, India

<sup>4</sup>NIMS Care Centre, Tirunelveli, Tamil Nadu, India

<sup>5</sup>Aarthi Scans and Diagnostics, Tirunelveli, Tamil Nadu, India



## ARTICLE INFO

### Article history:

Received 20-05-2021

Accepted 02-06-2021

Available online 24-06-2021

### Keywords:

Steroids

Osteoporosis

Vertebral fracture

Zoledronic acid

Rheumatoid arthritis

## ABSTRACT

Rheumatoid arthritis is one of the common inflammatory diseases affecting predominantly women. Steroids and anti-inflammatory drugs have been used for decades in managing this condition. Long term steroids have potentially devastating consequences in any multisystem disease and commonly described side effects include Cushing's syndrome, diabetes and osteoporosis. Fragility fractures are more common in these patients.

We report a patient with back pain and osteoporotic vertebral collapse whose neurological weakness was diagnosed and surgical fixation was done to help the patient improve dramatically. Steroids cause an osteoporotic collapse of the vertebra i.e. fragility fracture and appropriate timely intervention would result in an excellent outcome. Collaboration with other specialists greatly helped to get the treatment early even during this covid pandemic.

This is an Open Access (OA) journal, and articles are distributed under the terms of the [Creative Commons Attribution-NonCommercial-ShareAlike 4.0 License](https://creativecommons.org/licenses/by-nc-sa/4.0/), which allows others to remix, tweak, and build upon the work non-commercially, as long as appropriate credit is given and the new creations are licensed under the identical terms.

For reprints contact: [reprint@ipinnovative.com](mailto:reprint@ipinnovative.com)

## 1. Introduction

Corticosteroids have been used in many inflammatory conditions across different specialities since their invention by Philip Hench in 1950. However, the irrational use of steroids can cause side effects, which can be in multiple systems causing high morbidity and mortality. Long term steroids cause Cushing's syndrome, obesity and diabetes.<sup>1</sup> Osteoporosis and fragility fractures are common in patients taking steroids.<sup>2</sup> This case is presented to highlight the complexity of diagnosis and management of steroid-related osteoporotic vertebral collapse<sup>3</sup> and the need other speciality inputs, especially during the Covid Pandemic.

## 2. Case Summary

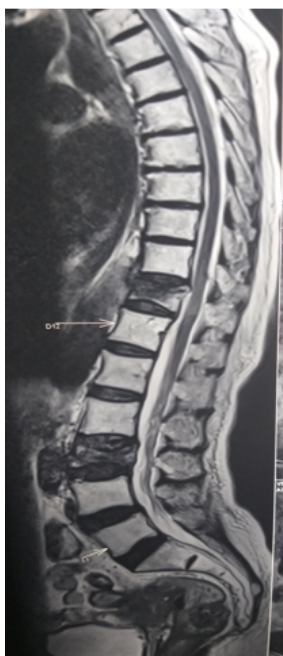We report a 68-year-old lady with a long history of rheumatoid arthritis and had been on prednisolone 5mg for the last 2 years, and anti-inflammatory drugs presenting with vomiting and unable to tolerate any medicines or food. She didn't have any fever or cough.

She was advised to stop steroids because of gastritis and oral candidiasis before this presentation. During the evaluation, she had features of hypoadrenalism with low sodium (Serum sodium: 128 mEq/L, Blood Pressure: 90/40 mmHg.) hypotension and fatigue, which improved with hydrocortisone injection. She also had recent onset of diabetes for 6 months and developed an abdominal wall wound, which was more like ulceration with clear margins.

\* Corresponding author.

E-mail address: [drsubramanian14@gmail.com](mailto:drsubramanian14@gmail.com) (S. Nallasivan).

After 3 days she complained of back pain and unable to weight bear. Examination showed paraparesis, with power 2/5 in legs, sensation reduced below L1 and normal bladder and bowel functions. She urgently had MRI of spine (Figure 1) that showed collapsed osteoporotic vertebra and impingement of the cord resulting in leg weakness. She was screened for Covid 19 as per institutional protocol and was found to have an RTPCR test negative. Her CT chest Showed fibrotic strands and no ground glass changes or nodes.



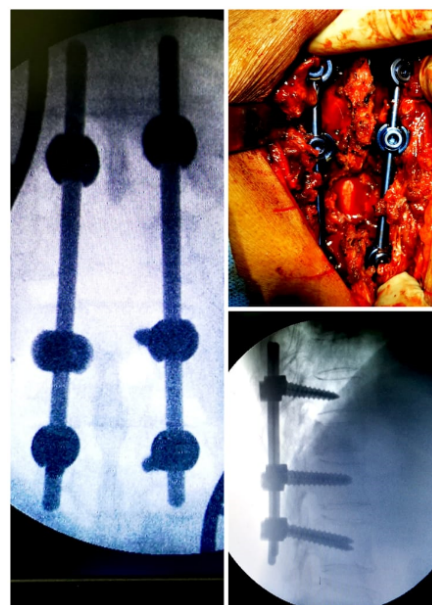
**Fig. 1:** MRI spine showing collapsed vertebra D11 and L3

She was evaluated for myeloma and metastasis from unknown primary and results were normal. She didn't remember any fall and she came in with features of Addisonian crisis due to sudden withdrawal of long term corticosteroids. While she was being prepared for surgery she had Zoledronic acid infusion. DEXA scan couldn't be done due to urgency. Abdominal wall wound was swabbed for culture.

She underwent urgent spinal decompression and fixation/stabilisation using D12, L1 screws, D11 laminectomy and D10 to L1 stabilisation Figure 2 and she was making slow recovery. Her neurological recovery was fast with passive and active movements of her legs.

### 3. Discussion

Corticosteroids are the main drugs in the therapeutic armamentarium of various inflammatory diseases across various specialities. Steroids causing complications have been proven for years and can have devastating consequences to the patients like fracture femur or spine,



**Fig. 2:** Operative imaging showing stabilised spine

diabetes and risk of cardiovascular disease<sup>4</sup> Over the counter remedies also do have steroids. Non Allopathic doctors too prescribe allopathic medications. Systemic steroids have to be used only for the short term. Our patient had steroids for 2 years and now had a total collapse of a vertebra with neurological consequences which was managed at the right time.<sup>5</sup>

### 4. Conclusion

Early and appropriate diagnosis with other specialist involvement helped to solve this patient's back pain. It is advised to review all medicines whenever patients come for consultation and flag up those Medicines for the patients to reconsider if the risk outweighs the benefit.

#### 4.1. Learning points

1. Any consultation will be incomplete unless the doctor reviews all medications for the patient
2. Long term steroids cause innumerable problems like diabetes, infections, fragile skin, osteoporosis and fragility fractures, hypertension, and obesity, to mention a few of the complications.<sup>6,7</sup>
3. Osteoporosis and fractures need acute intervention and long term treatment as National Osteoporosis Framework guidance.<sup>4</sup>

### 5. Acknowledgements

I would like to thank the patient and family, the specialists involved in this patients care and the neurosurgeon for a swift response during covid too.

## 6. Source of Funding

No financial support was received for the work within this manuscript.


## 7. Conflict of Interest

The authors declare they have no conflict of interest.

## References

1. van Staa T, Leufkens H, Cooper C. The Epidemiology of Corticosteroid-Induced Osteoporosis: a Meta-analysis. *Osteoporos Int.* 2002;13(10):777–87. doi:10.1007/s001980200108.
2. Kanis JA, Johansson H, Oden A, Johnell O, de Laet C, Melton LJ, et al. A Meta-Analysis of Prior Corticosteroid Use and Fracture Risk. *J Bone Miner Res.* 2004;19(6):893–9. doi:10.1359/jbmr.040134.
3. Liu D, Ahmet A, Ward L. A practical guide to the monitoring and management of the complications of systemic corticosteroid therapy. *All Asth Clin Immun.* 2013;.
4. Cosman F, Beur SJD, Leboff MS, Lewiecki EM, Tanner B, Randall S, et al. Clinician's Guide to Prevention and Treatment of Osteoporosis. *Osteoporos Int.* 1925;(10):2359–81.
5. Buckley L, Guyatt G, Fink HA, Cannon M, Grossman J, Hansen KE, et al. American College of Rheumatology Guideline for the Prevention and Treatment of Glucocorticoid-Induced Osteoporosis. *Arthritis Care Res (Hoboken).* 1969;69(8):1095–110.
6. Porter JL, Varacallo M. Osteoporosis; 2020. Available from: <https://www.ncbi.nlm.nih.gov/books/NBK441901/>.
7. Johnston CB, Dagar M. Osteoporosis in Older Adults. *Med Clin North Am.* 2020;104(5):873–84. doi:10.1016/j.mcna.2020.06.004.

## Author biography

**Subramanian Nallasivan**, Assistant Professor and Consultant Rheumatologist  <https://orcid.org/0000-0002-1840-0518>

**Raja S Vignesh**, Consultant Neurosurgeon

**Arunkumar Govindarajan**, Consultant Radiologist

**Cite this article:** Nallasivan S, Vignesh RS, Govindarajan A. Excellent outcome of a patient with acute back pain and osteoporotic fracture- A case report. *IP Int J Orthop Rheumatol* 2021;7(1):50-52.