

Osteochondroma of proximal end fibula causing common peroneal nerve compression: A rare case presentation

Nitin Bansal¹, Amrinder Singh^{2,*}, Gaurav Jain³, Swapnil Sharma⁴

¹Associate Professor and Head of unit, ²Assistant Professor, ^{3,4}Senior Resident, Dept. of Orthopaedics, Adesh Institute of Medical Sciences and Research, Bathinda, Punjab

*Corresponding Author:

Email: dr.ammy27@gmail.com

Abstract

Osteochondroma is ectopic calcification in physal plate causing a bony outgrowth with a cartilage cap. Osteochondroma grows till the growth plate is open. Osteochondroma constitutes 10% of all bone tumours and, among these, 35% (20–50%) of the benign tumours. The proximal fibula is rare site for an Osteochondroma causing a common peroneal nerve compression. We are presenting a case of a 12 year old male presented to us with the complaint of swelling over the lateral aspect of the left knee with decreased sensation of the dorsum and lateral border of the ipsilateral foot with weakness in dorsiflexion of ankle. X-ray showed bony out growth from the postero-lateral aspect of the fibula neck just beneath the physis. MRI showed bony out growth with a cartilaginous cap and the size of the lesion coincide with size as in x-ray. Marginal resection of the lesion was done along with exploration of the common peroneal nerve. The patient immediately postoperatively relieved from pain. A follow up of 3 months showed no tingling sensation and numbness over dorsum and lateral border of affected foot and power of dorsiflexion of ankle increased to 5/5.

Keyword: Osteochondroma, Solitary, Exostosis, Proximal fibula, Head of fibula, Nerve compression, Common peroneal nerve.

Case Report

A 12 year old male presented to us with the complaint of swelling over the lateral aspect of the left knee with decreased sensation of the dorsum and lateral border of the ipsilateral foot with weakness in dorsiflexion of ankle for last one year. Initially there was a small swelling of peanut size which gradually increases over a period of time. Patient experienced tingling and numbness with weakness in left foot 2-3 months ago which gradually increased.

On clinical examination there was a bony hard, globular, non-mobile swelling with smooth margins of size approximately 2 cm X 3cm over the postero-lateral aspect of the head of fibula. On examination the power of ankle dorsiflexion of the ipsilateral foot was 3/5 according to Medical research council (MRC) muscle scale and decreased sensation over the dorsum and lateral border of foot. X-ray showed bony out growth from the postero-lateral aspect of the fibula neck just beneath the physis. MRI showed bony out growth with a cartilaginous cap and the size of the lesion coincide with size as in x-ray. Other lab reports were normal.

Under spinal anaesthesia, patient was positioned supine with a sandbag underneath buttock of the affected side. A tourniquet without exsanguination was used. With Postero-lateral approach, a linear incision was taken starting just posterior to fibula, along posterior border of biceps femoris tendon and after a careful surgical dissection common peroneal nerve was explored and safely retracted anteriorly by using a strip of corrugated rubber drain, muscles

were stripped and tumour was exposed. The common peroneal nerve was in close proximity to the outgrowth and was showing sign of irritation (increased vasa nervosum and slight thickening). Marginal resection of tumour was done and was send for histopathological examination. I.V antibiotics were started one day prior to surgery and was continued for two days, along with analgesics after surgery. Above knee posterior slab was applied with knee in 30 degree of flexion and ankle in neutral position and later on ROM of knee and ankle was started

Histopathological report confirmed lesion as benign Osteochondroma. Patient's recovery was uneventful. Follow up at 3rd month showed no tingling sensation and numbness over dorsum and lateral border of affected foot and power of dorsiflexion of ankle was increased to 5/5.

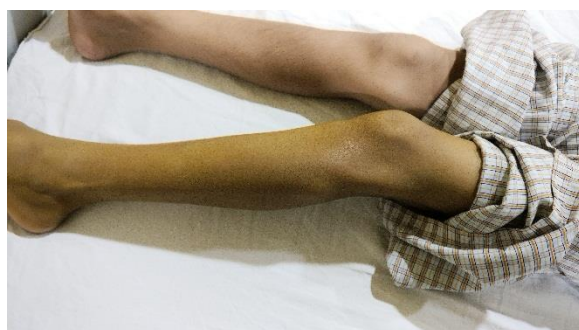

Fig. 1

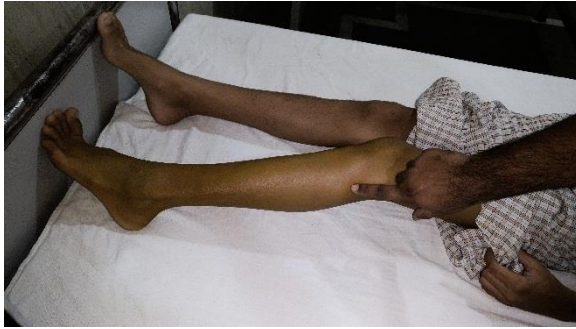

Fig. 2

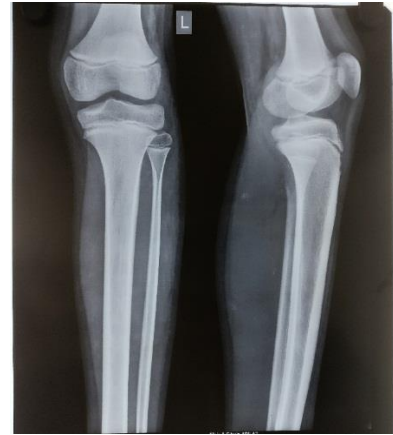

Fig. 4

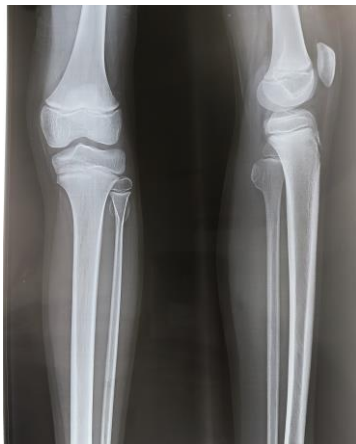

Fig. 3

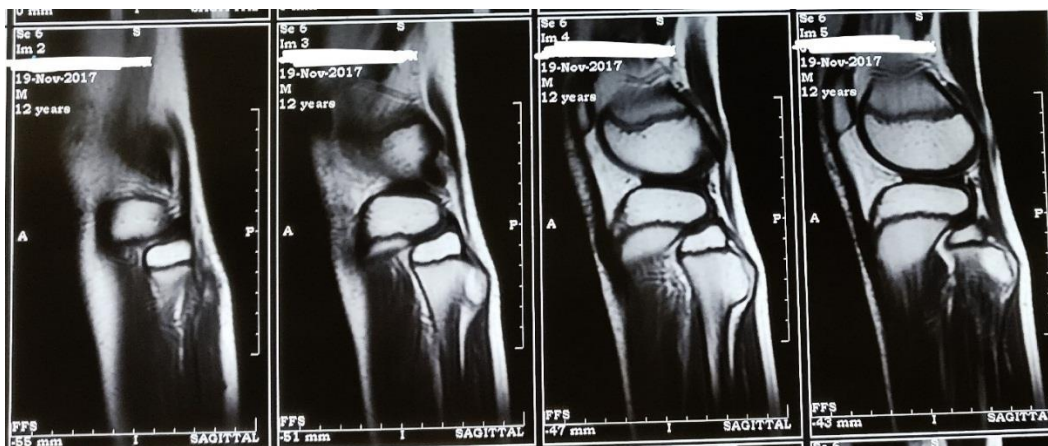


Fig. 5

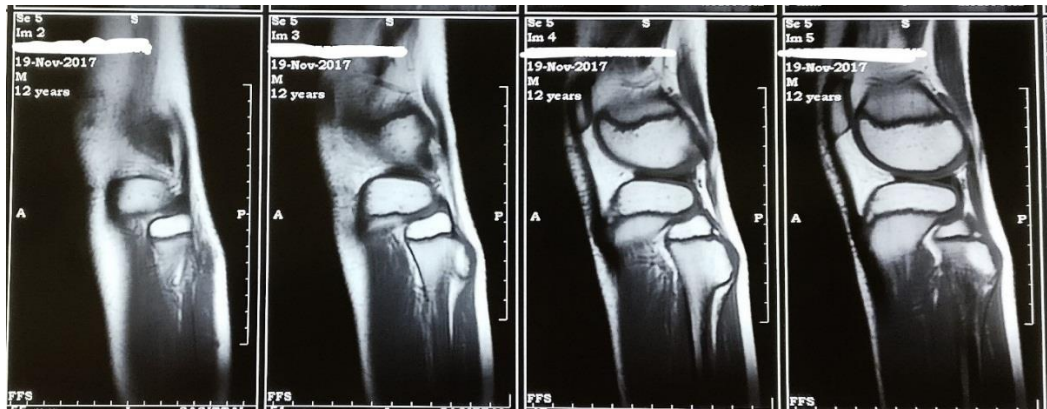


Fig. 6

Discussion

Osteochondroma is ectopic calcification in physal plate causing a bony outgrowth with a cartilage cap. Osteochondroma grows till the growth plate is open. Osteochondroma constitutes 10% of all bone tumours and, among these, 35% (20–50%) of the benign tumours.^(2,6) Single lesions are found in 85% of the individuals diagnosed with osteochondroma.⁽³⁾ The exostosis is commonly identified during childhood or adolescence.^(1,2) The incidence of primary bone tumours in the fibula is 2.5%.⁽¹⁾ For Osteochondroma The proximal fibula is a unusual site for. Osteochondroma are mostly benign tumour and donot have much symptoms of their own expect for the visible swelling. Sometimes they causes compression in nearby structure which become a concern when the structures is neurovascular bundle. In our case the swelling was asymptomatic for 8-9 months and later caused compression over the commom peroneal nerve due to which decision of removal of tumour mass before the physal closure was taken. the patient at 3 month followup showed complete recovery of sensory and motor deficit of the affected limb. The question of recurrence remain unanswered which the time will tell.

Conclusion

Osteochondromas are among the common benign tumour of bone. They increases in size till skeletal maturity and may remain unharmlful throughout life, but if they cause progressive deformity (due to closeness to the joint) or neurological deficit as in this case, one should plan for early excision with long follow-up of the patient (till they achieve skeletal maturity) for any recurrence.

References

1. Unni K. Dahlin's Bone tumours: General Aspects and Data on 11,087 Cases. Philadelphia: Lippincot-Raven Publishers; 1996
2. Khurana J., Abdul-Karim F., Bovée J.V.M. Osteochondroma. In: Fletcher C.D., Unni K.K., Mertens F., editors. Pathology and genetics of tumours of

the soft tissues and bones. IARC Press; Lyon: 2002. pp. 234–237.

3. Unni K.K. 5th ed. Thomas; Springfield: 1996. Osteochondroma. Dahlin's bone tumours: general aspects and data on 11,087 cases; pp. 11–23.
4. Dorfman H.D., Czerniak B. Mosby; St. Louis: 1998. Osteochondroma. Bone tumours; pp. 331–346.
5. Resnick D., Kyriakos M., Greenway G.D. Osteochondroma. In: Resnick D., editor. Diagnosis of bone and joint disorders. 3rd ed. Saunders; Philadelphia: 1995. pp. 3725–3746
6. Scarborough M.T., Moreau G. Benign cartilage tumours. Orthop Clin North Am. 1996;27(3):583–589.