

Minimal implant fixation for schatzker type V And VI osteoporotic tibial plateau fractures

Keyur Shah¹, Sulay Sachdev^{2,*}, Meet Mehta³, Jaimin Patel⁴

¹Assistant Professor, ^{2,3,4}Resident, ³Professor, BJ Medical College & Civil Hospital, Ahmedabad, Gujarat, India

***Corresponding Author:**

Email: sullusachdev@gmail.com

Abstract

Introduction: Knee being one of the major weight bearing joints of the body, fractures around it will be of regnant importance. This study is to analyse outcomes in Schatzker type V and type VI fractures treated only with medial plates, which are usually treated with dual plating.

Materials and Methods: 30 osteoporotic patients were selected having type V and type VI fractures of tibial plateau, fractures were selected from March 2016-March 2017 from Civil Hospital Ahmedabad, who were treated only with medial plates.

These patients were followed for a period of six months and functional outcome was evaluated based on the Oxford Knee Criteria.

Results: 30 patients who completed six months follow up after surgery were included in our study.

All of them had satisfactory articular reduction and good alignment on coronal and sagittal planes which was assessed by AP and lateral X rays.

90% returned to their preinjury levels of activity within 6 months of time. Only 1 of them had deep infection followed by implant removal. Functional outcome was excellent in 22 patients and good in 8 patients as assessed by Oxford Knee Score.

Conclusion: Tibia being a subcutaneous bone, is prone to more hardware complications like infections and implant impingement. To overcome these complications, minimal implant fixation is must.

Medial plating in bicondylar tibial fractures serves as a very good option which provides early mobilization in patients which not only takes care of the soft tissue but also leads to early mobilization of the patient.

Keywords: Tibial Plateau Fracture, Schatzker type V and VI, Minimal hardware, Medial plating.

Introduction

Tibial plateau fractures are one of the commonest intra-articular fractures. Owing to its complex anatomy and extensive soft tissue involvement treatment of such fractures is cumbersome. These fractures are commonly associated with articular comminution, depression, metaphyseal extension, ligament injuries and compartment syndrome.

Amongst tibial plateau fractures isolated medial condyle fractures are noted in 10-23% while bicondylar are found in 10-30% whereas majority of them are only lateral tibial condyle.⁽¹⁾ Plateau fractures are very commonly associated with extensive tissue damage and neurovascular damage because these are due to high velocity trauma.

Schatzker classification is used by the doctors for assesment of injury, management and for final outcome. Tibial plateau fractures are classified into six categories according to Schatzker and is arranged in increasing severity of the trauma to the bone. First four involves only one condyle and type V and VI are bicondylar. Fracture pattern in the schatzker help in deciding the modality of the treatment.

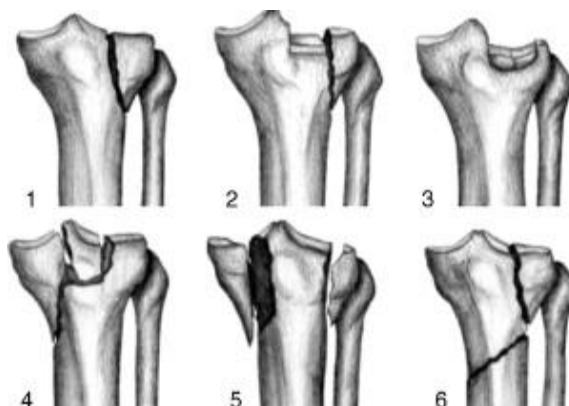


Fig. 1: Schatzker classification

The ideal treatment of high-energy tibial plateau fractures remains controversial

Anatomical congruity and alignment can be best achieved by open reduction and rigid fixation which helps in early knee mobilization. On other hand open reduction leads to wound complications especially if done through compromised soft tissue.

With better understanding in biomechanics, principles of fixation availability of implants, soft tissue care, availability of antibiotics open reduction became the treatment of choice. Conventionally bicondylar fractures were treated with dual plating which were having higher incidences of complications like implant impingement infection.

In order to circumvent these complications we are aiming our study to evaluate functional outcome in tibial plateau fractures by using only medial plates.

Materials and Method

This is a retrospective study of 30 osteoporotic patients selected with tibial plateau fractures treated by open reduction and internal fixation in Civil Hospital, Ahmedabad, from March 2016-March 2017.

Exclusion Criteria

- Type I to type IV Schatzkertibial plateau fracture.
- Open fractures
- Pathological fractures
- Age > 60 years
- Primary neurovascular deficit
- Fractures in patients with head injury and ploy trauma
- Patient with comorbidities

Pre-operative management:

After primary stabilization of vitals, as per ATLS protocol in casualty all patients were assessed clinically and radiologically. All the patients at the time of injury were assessed clinically for neurovascular deficit as well as for soft tissue injury. Radiologically patients were assessed with AP and Lateral full length tibia with knee joint radiographs along with 3D CT scan for better understanding of fracture pattern, intraarticular extension and classification according to Schatzker classification.

The ones with soft tissue injury with skin oedema or blisters were treated with Distraction fixator followed by limb elevation and glycerine application. Antibiotics were given for a minimum of 5 days. After proper management of soft tissue and proper skin coverage, were planned for reduction of fracture.

Surgery:

All surgeries were done under image intensifier guidance and strict aseptic precautions in supine position on plain table.

Post-operative management:

In immediate post-operative period, patient is given limb elevation and crepe support. Depending on pain tolerance of the patient, quadriceps strengthening exercises are started and knee and ankle mobilized. I.V. antibiotics were given for 3 days followed by oral antibiotics for a period of 2 weeks. After suture removal, patients were advised non weight bearing walking.

Follow up:

In our follow up protocol, we called up patients on 1 month and 6 months post-surgery. On each follow up, patients were assessed clinically by Rasmussen score and radiologically by AP and Lateral radiographs.

According to Rasmussen score, patients were divided into following categories:

Score 9-10 excellent

Score 7-8 good

Score 5-6 fair

Score <5 poor

Once signs of union were visualized partial weight bearing was allowed. All data was statistically analysed in relation with significant p value of less than 0.05

Results

- a. 30 patients having Schatzker type V and Type VI, treated with medial plating were selected.
- b. The age of patients varied between 20-60 mean being 40.
- c. 20 of them were male while 10 were female.
- d. In all of them, mode of injury was RTA that is high velocity injury.
- e. Out of 30, 20 of them had soft tissue swelling, either skin oedema or blisters.
- f. 10 patients were treated immediately after injury with internal fixation while 20 underwent distraction fixator initially.
- g. Mean time of operation was 7 days from admission.
- h. Average operating time was 90 mins.
- i. Hospital stay varied from 5 days to 20 days, mean being 12 days.
- j. Complications were seen in 7 patients. 5 had superficial infection out of which 4 recovered satisfactorily with higher antibiotics for a long period of time. 1 needed debridement and eventually removal of implant. 1 of them had joint stiffness but was able to ambulate independently.
- k. Average time of callus formation was found to be 12 weeks. Concomitant injuries didn't hamper the bone healing but soft tissue recovery occurred in an uneventful manner.

Table 1: Rates of complication

Complication	Number of patients
Infection (superficial)	5
Knee stiffness	2
None	23
Total	30

- l. All patients showed movement similar to their preoperative range except 1 in whom stiffness developed.
 - m. Mean range of flexion was 116.2 degree.
 - n. While mean range of extension was minus 1 degree.
- According to Rasmussen criteria following were results

Table 2

Grade	No. of patients
Excellent	18
Good	7
Fair	3
Poor	2

Discussion

Upper tibial compartments being closed and compact, their fractures are associated with excessive soft tissue swelling.

Very often, upper tibial fractures present with blisters and reddening of skin.

Rarely, they also present with compartment syndrome.

In order to prevent these complications, damage control surgery is performed by keeping distraction fixator which accelerates soft tissue healing.

Along with fixator, Glycerine magnesium sulphate dressing is also used, which promotes early soft tissue healing.

Once the skin conditions become favourable, patients are called up for definitive surgery.

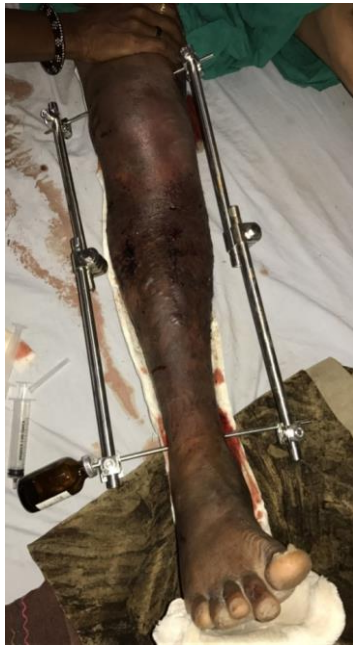

Fig. 2: Showing distraction fixator in patients with severe soft tissue swelling and blisters

The aim of our study was to evaluate the outcome of medial plating in Schatzker type V and Type VI fractures.

Type V and type VI are bicondylar fractures and are treated conventionally with dual plating. Tibia being subcutaneous bone is prone to infection.

Only lateral plate will lead to varus collapse resulting in premature osteoarthritis.

Above complications being rare with only medial plates, can become a good option in minimal implant fixation.

These are the fractures which cannot be treated conservatively and are prone to infection, hence minimal implant fixation is the best way of treating such fractures.

Most of the patients in our study were male but it was not significant.

Most of the patients having these fractures were from active age group, mean age being 40 attributing such fractures to high velocity trauma.

These fractures being very common in young age groups, proper reduction is the necessity which could only be achieved by internal fixation.

Since infection is the major complication in such fractures, minimal exposure is must for reduction of such fractures. The other complication faced is knee stiffness. In earlier days, many tibial plateau fractures were treated conservatively, which later on follow with knee stiffness.

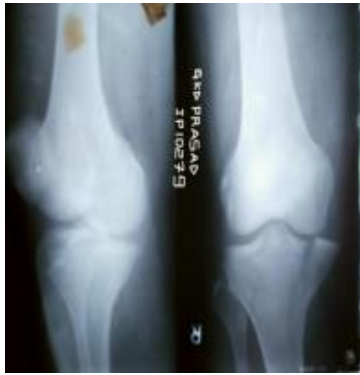Both these complications can be circumvented by using only medial plate, where there are less chances of infection and early mobilisation.

By using only medial plates, satisfactory intra articular reduction was achieved in all the patients with medial plating.

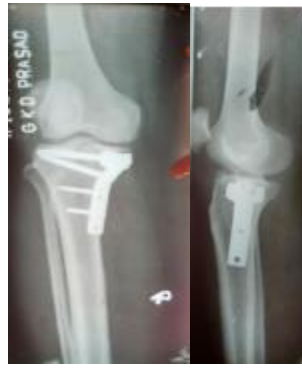Conclusion

- Damage control surgery is must for control of soft tissue injury.
- ORIF is must for accurate reconstruction of articular surface and early mobilization of the patient.
- Excessive hardware usage is associated with complications like infection and implant impingement.
- Medial plating alone in Schatzker type V gives satisfactory results in reduction of fracture.
- Satisfactory range of movement could be achieved in patients treated with medial plating.

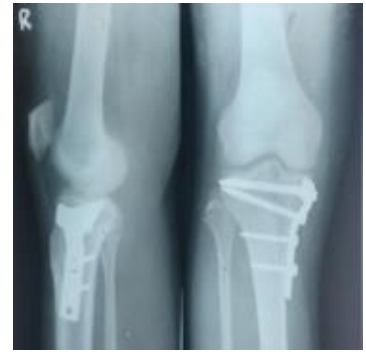Case 1



Pre op X-ray



Immediate post op
Fig. 3



Follow up

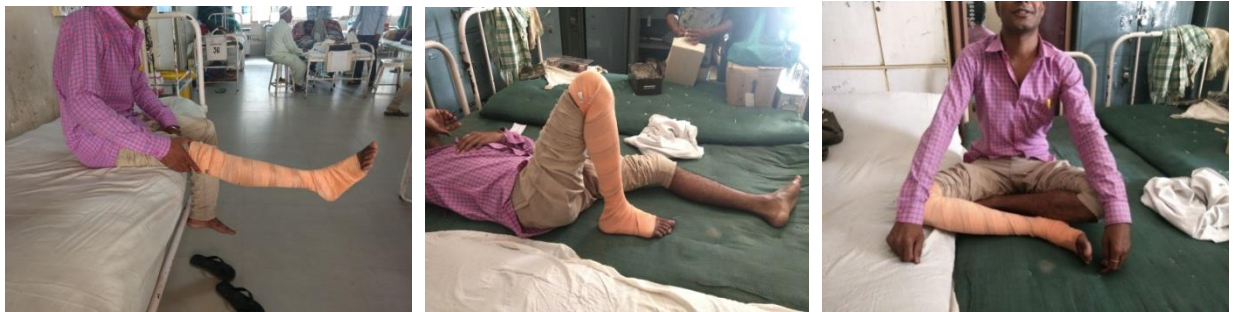

Fig. 4: Clinical image showing flexion extension and cross leg sitting following surgery

Case 2

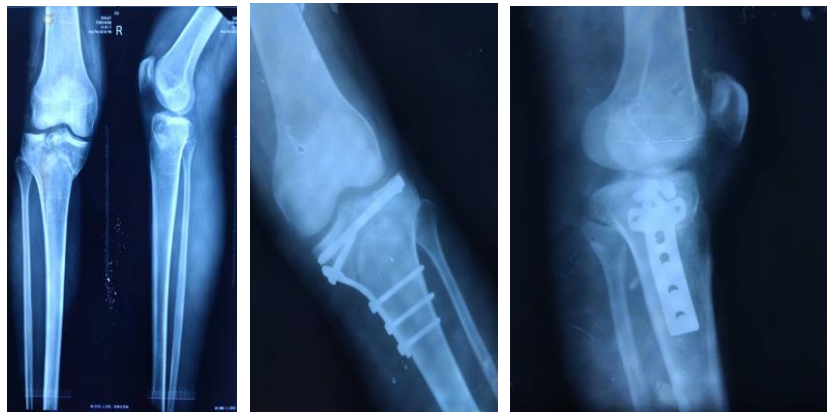


Fig. 5

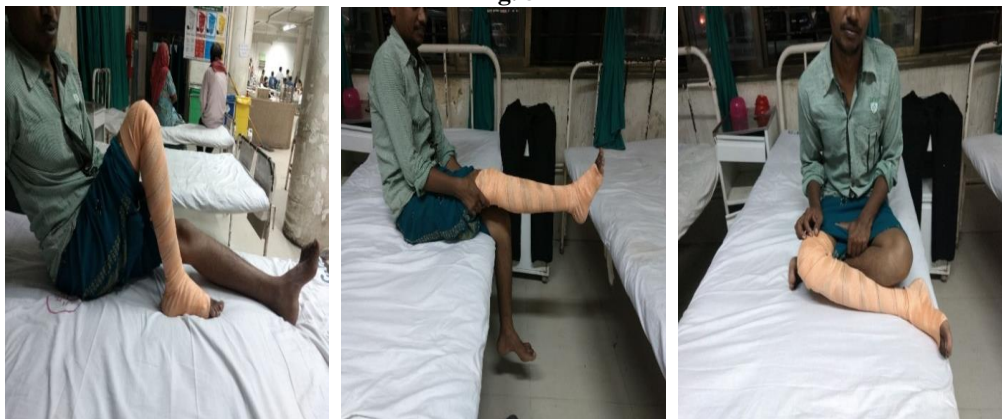

Fig. 6: Clinical image showing flexion extension and cross leg sitting following surgery

References

1. J.L. Marsh, Tibial Plateau Fractures, chapter 53 in Rockwood and Green's fractures in adults, Bucholz RW and Heckman JD, 7th Edition. Vol 2: Philadelphia, Lippincott Williams and Wilkins 2010;1780-1831.
 2. De Boeck H, Opdecam P. Posteromedial tibial plateau fractures. Operative treatment by posterior approach. ClinOrthopRelat Res 1995:125-8.
 3. Horwitz DS, Bachus KN, Craig MA, Peters CL. A biomechanical analysis of internal fixation of complex tibial plateau fractures. J Orthop Trauma 1999;13:545-9.
 4. Borrelli J, Jr., Ellis E. Pilon fractures: assessment and treatment. OrthopClin North Am 2002;33:231-45, x.
 5. Patterson MJ, Cole JD. Two-staged delayed open reduction and internal fixation of severe pilon fractures. J Orthop Trauma 1999;13:85-91.
 6. Sirkin M, Sanders R, DiPasquale T, Herscovici D, Jr. A staged protocol for soft tissue management in the treatment of complex pilon fractures. J Orthop Trauma 1999;13:78-84.
 7. Charlie Lewis; Does the mode of fixation of tibial plateau fractures, i.e. external fixation versus internal fixation influence the time to union? A systematic review of the literature.
-