

Content available at: <https://www.ipinnovative.com/open-access-journals>

IP International Journal of Orthopaedic Rheumatology

Journal homepage: [www.ijor.org](http://www.ijor.org)

## Original Research Article

## To study functional outcome of single level discectomy by fenestration method in lumbar disc prolapse- A prospective study

Saksham Sharma<sup>1</sup>, Jiya Lal Bairwa<sup>2</sup>, Harishankar Meena<sup>2</sup>, Sachin Kumar Pachori<sup>1,\*</sup>, Mahendra Singh Tak<sup>2</sup>

<sup>1</sup>Dept. of Orthopedic, SJP Medical College, Bharatpur, Rajasthan, India

<sup>2</sup>Dept. of Orthopedic, Dr. Sampurnanand Medical College (SNMC), Jodhpur, Rajasthan, India



## ARTICLE INFO

## Article history:

Received 17-05-2023

Accepted 04-07-2023

Available online 27-07-2023

## Keywords:

Fenestration

Discectomy

Lumbar disc prolapse

## ABSTRACT

**Background:** Low backache pain affects every population and is one of the most common clinical symptoms encountered in medical practice. Approximately 70 - 80% of people have experienced low back pain at some point of time in life. The annual prevalence of low back pain ranges from 15-45%. The major cause of low back pain leading to severe morbidity throughout the world that affects mainly the young working-class population is lumbar disc prolapsed. Various retrospective and some prospective reviews of fenestration disc surgeries orthopaedic vary greatly, with good results ranging from 46-97% and a reoperation rate of 09%. The present study was conducted to evaluate the results of single-level discectomy by fenestration method in Lumbar disc prolapse.

**Materials and Methods:** Total thirty cases of lumbar disc prolapsed treated with fenestration and discectomy satisfying inclusion and exclusion criteria treated in the Facility based tertiary care centre department of Orthopedics of Dr. S. N. Medical College and associated group of hospital, Jodhpur were studied.

**Results:** In our study, Out of 30 patients majority of 25 (83.3%) patients showed good outcomes, followed by 04 (13.33%) patients had fair outcomes, and 01 (3.33%) patient had poor outcomes. Total complications are 4 (13.33%), and the most common complication is superficial wound infection 2 (6.67%).

**Conclusion:** By considering all aspects, fenestration, and discectomy is a better technique with the advantage of less tissue injury, good spinal function, smooth patient recovery, improved working status with early rehabilitation and maintained clinical efficacy

This is an Open Access (OA) journal, and articles are distributed under the terms of the [Creative Commons Attribution-NonCommercial-ShareAlike 4.0 License](https://creativecommons.org/licenses/by-nc-sa/4.0/), which allows others to remix, tweak, and build upon the work non-commercially, as long as appropriate credit is given and the new creations are licensed under the identical terms.

For reprints contact: [reprint@ipinnovative.com](mailto:reprint@ipinnovative.com)

### 1. Introduction

Low back pain is one of the most common clinical symptoms encountered in practice. Low back pain is a symptom, not a disease. Approximately 70% to 80% humans have experienced low back pain at some point of time in life.<sup>1</sup> Lifetime incidence of low back pain in vary from 50% to 70% including sciatica among 40%, but clinically significant sciatica requiring special attention

accounts for only 4-6% cases degeneration of disc due to various factors that can lead to prolapse of the intervertebral disc into intervertebral foramina, especially at L4-L5 and L5-S1 Level. The L3-L4 & L2-L3 Levels account for the majority of remaining prolapse. Since the outcome of surgery depends on many factors, such as careful selection of patients, detailed clinical history, and physical examination supported by relevant radiological investigations helps to differentiate disc prolapse from other causes of low back and sciatica.<sup>2</sup> Laminectomy and discectomy is a common procedure performed for the

\* Corresponding author.

E-mail address: [drsakshamthesage@gmail.com](mailto:drsakshamthesage@gmail.com) (S. K. Pachori).

management of disc prolapse, but extensive laminectomy may cause destabilization of the spine later.<sup>3,4</sup> Fenestration discectomy is reputed to be less time-consuming, with less blood loss, and it does not compromise the stability of the spine column compared to extensive laminectomy.<sup>5</sup>

Fenestration discectomy is stood the test of time for many decades for the treatment of lumbar disc prolapsed. Therefore, this study aims to find out the functional outcome on basis joa's low backache score in patients undergoing single-level discectomy by fenestration method in lumbar disc prolapsed and find out the complication following fenestration method.

## 2. Materials and Methods

We conducted a hospital-based Prospective observational study at the Facility based tertiary care center department of Orthopedics of Dr. S. N. Medical College and the associated group of hospital, Jodhpur was studied from August 2020 to July 2021. Proper approval from the hospital ethical committee was taken for the study.

### 2.1. Sample size

Sample size was calculated at a 95% confidence interval to verify an expected 86% prevalence of excellent to good functional outcome post fenestration and discectomy in lumbar disc prolapse cases at a relative allowable error of 15%. the sample size was calculated using the formula for the sample size for estimation of proportion –

Sample size was calculated to be minimum of 28 subjects. For study purpose sample size was rounded off to 30 subjects.

### 2.2. Inclusion criteria

1. Age 18-55 years.
2. Failure to respond to non-operative treatment.
3. Presence of positive root tension signs with or without neurological deficits.
4. A good CLINICO- radiological co-relation (good radiological means that patient clinical finding should be matched with radiological finding and there should not be any mismatched like in term of side and level.
5. Single level lumbar disc prolapse.

### 2.3. Exclusion criteria

1. Prior lumbar spine surgery.
2. Vertebral fractures.
3. Radiological evidence of facet joint arthritis.
4. Any lumbar spinal infection.

All patients underwent discectomy by fenestration method in the prone position. The level and type of disc protrusion were observed intraoperatively. Postoperatively the patients

followed up in the immediate post-operative period, 1 month and 6 months after the surgery.

The Japanese orthopaedic association low backache score would be used pre and post-op to assess the functional outcome

The outcome designation

1. Good 75 to 100 % improvement.
2. Fair 50 to 75% improvement.
3. Poor below 49%.

The improvement in pain and neurological deficit and its complication also noted

**OPERATIVE PROCEDURE** Open fenestration and discectomy

#### 2.3.1. Approach

Firstly level marking in c-arm than a mid-line vertical incision over the affected interspace of 2-4cms is made after the back has been thoroughly painted and draped. The incision deepened to the subcutaneous tissue and deep fascia. The lumbodorsal fascia is incised, stripping the paraspinal muscle from the spinous process and laminae of the vertebrae on the affected side, and McCulloch self-retaining retractors are applied. The laminae are carefully nibbled and the ligmentum flavum is removed using a Kerrison rongeur. After the thecal sac has been exposed adequately the dura is retracted medially and nerve root is inspected. The nerve root is retracted medially using a blunt dissector in order to visualize the underlying disc. An extruded fragment or a bulging disc removed by disc forceps. Aftercare patient was allowed to turn in bed. For pain relived, giving injectable and oral NSAIDS. patient was allowed out of bed after 24 to 48 hours, the patient was advised of isometric abdominal and lower extremity exercises. heavy weight lifting, forward bending, and stooping are prohibited for 6 weeks. Back strength exercises were advised from the second week. The patient was advised to return to occupation after 6 to 8 weeks .patient was called at 1 month and 6 months of surgery and clinically evaluated and scoring was done by joa score.

#### 2.3.2. Statistical analysis

Data thus collected were entered in Microsoft Excel Sheet by the investigator himself on same day to minimize data entry bias if any analyzed using SPSS version 24. The results were presented as percentages, and the Chi-square test was used to assess the association. The P-value of less than 0.05 was taken as the level of significance.

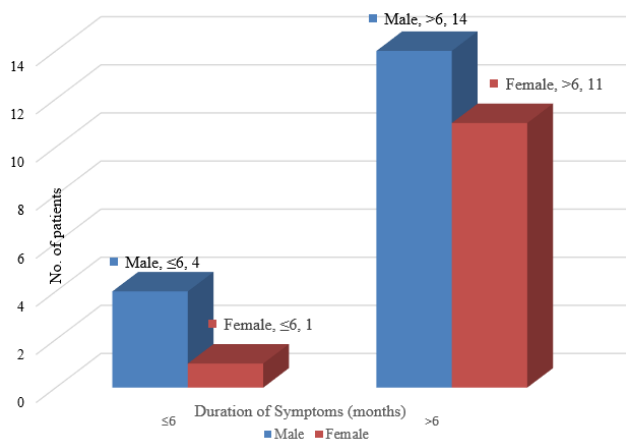
## 3. Results

This study consists of 30 cases of lumbar disc prolapse treated by fenestration and discectomy in 2020-21. Patients' ages ranged from 18 to 55 years, with mean age is 34.6 years.

**Table 1:** Age-wise distribution of study population

Age (yrs)	No. of patients	Percentage
18-30	14	46.67
31-40	7	23.33
41-50	6	20.00
≥51	3	10.00
Total	30	100.00

Following table depicts the age distribution of study subjects. Maximum (46.67%) patients are in the 18-30 year age group, and minimum (10%) patients in ≥ 51 year age group. The mean age 34.6 years. In our study, males are 18 and females are 12. (Table 1)



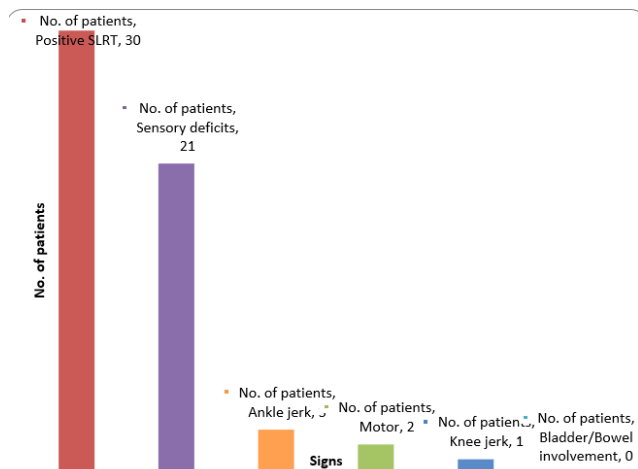
**Fig. 1:** Duration of symptoms with gender

In the present study male cases 4 (13.33%) and female is 1 (3.33%) in ≤6 months in symptoms of duration. 14 (46.67%) patients are male and 11 (36.67%) had females in >6 months in symptoms of duration. 27 out of 30 had low back pain, followed by 30 with radicular pain and 6 patient complained of weakness in the lower extremities. All patients received a trail of conservative treatment in the form of bed rest and physiotherapy without significant improvement.

On examination, the most common finding is a positive SLRT followed by a sensory deficit.

**Table 2:** Distribution of Japanese orthopedic association score

Score	JOA Score		JOA Score	
	Pre-op		Post-op	
	N	%	N	%
0-5	19	63.33	0	0.00
6-10	11	36.67	1	3.33
11-15	0	0.00	29	96.67
Total	30	100.00	30	100.00
Mean±SD	5.3±0.98		13.00±0.90	



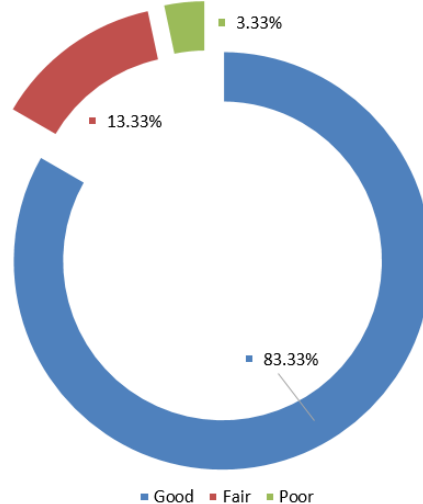
**Fig. 2:** Distribution of signs

Preop Japanese orthopaedic mean score 5.3±0.98 and post operative Japanese orthopaedic mean score 13.00±0.90. (Table 2)

**Table 3:** Distribution of level of prolapse

Level of disc prolapse	No. of patients	Percentage
L4-L5	20	66.67
L5-S1	9	30.00
L3-L4	1	3.33
L2-L3	0	0.00
Total	30	100.00

In present study L4-5 disc prolapse 20(66.67%) was the commonest level, followed by L5-S1 and L3-L4 disc prolapse 9(30%) and 1 (3.33%) respectively. (Table 3)



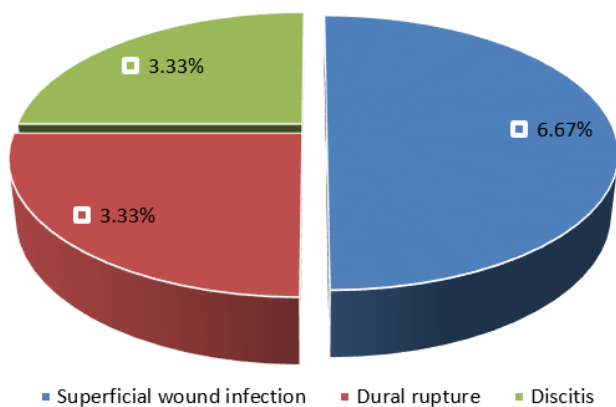
**Fig. 3:** Distribution of outcome

The results of the surgery were analyzed based on the Japanese orthopaedic score. Based on Japanese orthopaedic score 25(83.33%) patients had good, 4(13.33%)fair and only 1(3.33%)poor surgical outcome.(Figure 3)

**Table 4:** Distribution of neurological with improvement status

Neurological deficit	No. of patients	Improved		Not improved	
		N	%	N	%
Sensory	21	17	80.95	4	19.05
Motor	2	2	100	0	0.00

17 of 21 patients with sensory deficits before surgery had improved strength after surgery and 2 patients with motor deficits improved. Four patients had persistent sensory deficit after surgery.(Table 4)



**Fig. 4:** Distribution of complications

Out of 30 patients, 4 (13.33%) having surgical complications, followed by 2(6.67%) were superficial wound infection, dural rupture 1(3.33%), and discitis 1(3.33%) having surgical complications. Infection is managed by I.v. or oral antibiotics according to culture and antibiotic sensitivity. Dural tears must be sutured with 6.0 or 7.0 proline with a round body cutting needle using a using simple or running locking stitch.<sup>6</sup>

#### 4. Discussion

Back pain due to lumbar intervertebral disc prolapse contributes to a chunk of problems related to back pain. Lumbar disc disease though not contribute to mortality, it contributes to morbidity and economic loss due to the number of work hours lost.<sup>7</sup> Prolapsed intervertebral disc occurs in about 5-10% of all backache patients and is a common cause of sciatica. Even a small prolapsed disc in the presence of a narrow spinal canal can lead to compression of the cauda equina and its roots. Mainstay treatment of lumbar disc prolapse has been removal of disc i.e., discectomy, though methods of discectomy differs.<sup>8,9</sup>

Spengler in 1982 described limited disc excision, only the ligamentum flavum and if necessary small portion of lamina inferiorly is removed to expose the prolapse disc space and the extruded disc were removed.<sup>10</sup> Daneyemez M.et al, in 1999 analyzed the outcome of 1072 surgically treated lumbar disc herniation. They stated that there are many new techniques that treated lumbar disc herniation, but also that the conventional standard discectomy is still the most acceptable method today. The result of disc surgery depends not only upon the degree of neurological impairment, operative technique, and skill but also upon the correct selection of cases.<sup>11</sup>

Aslam M et al (2015) conducted the follow-up analysis as per modified mac Nab's criteria showed excellent result in 15 patients, good in 4 patients and fair in 1. Discectomy by fenestration offers sufficient and adequate exposure for lumbar disc excision. Advantages over conventional discectomy are smaller incision, lesser morbidity, shorter convalescence, early return to work and comparable overall results.it can even be performed in peripheral centers where recent microscope and endoscopic facilities are not available.<sup>12</sup>

Kumar PA et al (2016) to evaluate this study the functional outcome of discectomy for lumbar disc prolapse with 30 cases treated with fenestration and discectomy and used the Japanese orthopaedic association low backache score to assess the outcome. Study results are achieved 86% excellent to good results, 10%of fair results with a complication rate of 3.3% only.<sup>13</sup> In our study, we used the joa questionnaire<sup>14</sup> to assess the functional outcomes in our patients.

#### 5. Limitations

However, this study has limitations. Our study had short-term follow up so we were not in a position to comment on long term follow-up of the same patients. Moreover, our study did not compare its results with latest technique of microdiscectomy which is a promising, less invasive technique to treat the same condition. Also, our study did not provide in depth insight into psychological factors affecting the functional outcome of surgery

#### 6. Conclusion

Our study concludes that the fenestration and discectomy is an extremely useful and effective surgery for the treatment of lumbar disc prolapse. Consistently good results (83.33%) in our study could be attributed to the proper selection of cases and a meticulous surgical protocol. The results of lumbar discectomy are good when there is an agreement between clinical presentation and imaging studies, as was seen in our study. We achieved results comparable to that achieved with fenestration. Microsurgical techniques may have some advantages in terms of a less invasive approach,

shorter hospital stay, etc., but one must understand the demands, requirements, and limitations of this technique. It also has a long learning curve and is technically a more demanding procedure in terms of the surgical skills of the surgeon and the equipment required. Thus, it is available only in multispecialty hospitals. Also, fenestration and discectomy is more cost-effective than fenestration. Therefore, for the Indian scenario, fenestration and discectomy is still the “Gold Standard” in the operative treatment of lumbar disc prolapse.

## 7. Clinical Message

In peripheral institutions, fenestration with disc excision is quite a reasonable method to surgically treat the indicated cases of the prolapsed disc. This procedure can be well performed even by an average spinal surgeon with adequate experience in the field of disc surgery with good functional outcome.

## 8. Conflict of Interest

None.

## 9. Source of Funding

None.

## 10. Acknowledgments

The authors would like to thank the staff of the Anaesthesia department, Radiology department, and Nursing department for helping us to carry out this study. The author would also like to thank the Orthopaedics department staff Prof and the head of the department. Dr. Mahesh bhat for their valuable input.

## References

- Anderson GB. Epidemiological features of chronic low back pain. *Lancet*. 1999;354(9178):581–5. doi:10.1016/S0140-6736(99)01312-4.
- Aslam M, Khan FR, Huda N, Pant A, Julfiqar M, Goel A, et al. Outcome of Discectomy by Fenestration Technique in Prolapsed Lumbar Intervertebral Disc. *Ann Int Med Den Res*. 2015;1(3):286–90.
- Hedtman A. Das sog. Post-diskotomiessyndrom/Fehlschläge der Bandscheiben-operation? *Z Orthop*. 1992;130:456–66.
- Loew F, Casper W. Surgical Approach to Lumbar Disc Herniations. In: *Advances and Technical Standards in Neurosurgery*. Advances and Technical Standards in Neurosurgery. vol. 5. Springer, Vienna; 1978. p. 153–74. doi:10.1007/978-3-7091-7062-5\_5.
- Mhaskar VA, Pai SN. Epidural Steroid Injection: A Convenient Short Term Alternative to Fenestration Discectomy in Lumbar Disc Herniation. *JSM Neurosurg Spine*. 2015;3(2):1057.
- Wang JC, Bohlman HH, Riew KD. Dural tears secondary to operations on the lumbar spine: Management and results after a two-year minimum follow-up of eighty-eight patients. *JBone Joint Surg Am*. 1998;80(12):1728–32.
- Kraemer J. Epidemiology. In: Weisel S, editor. *The lumbar spine*. Philadelphia: W.B. Saunders Company; 1996. p. 1–42.
- Mixter WJ, Barr JS. Rupture of intervertebral discs with involvement of spinal canal. *New Eng J Med*. 1934;211:210–5. doi:10.1056/NEJM193408022110506.
- Kleinpeter G, Markowitsch MM, Bock F Percutaneous endoscopic lumbar discectomy: Minimally invasive, but perhaps only minimally useful? *Surg Neurol*. 1995;43(6):534–9.
- Spengler DM. Lumbar discectomy. Results with limited disc excision and selective foraminotomy. *Spine (Phila Pa 1976)*. 1982;7(6):604–7.
- Daneyemez M. Outcome analyses in 1072 surgically treated lumbar disc herniations. *Minim Invasive Neurosurg*. 1999;42(2):63–8.
- Aslam M, Khan FR, Huda N, Pant A, Julfiqar M, Goel A, et al. Outcome of Discectomy by Fenestration Technique in Prolapsed Lumbar Intervertebral Disc. *Ann Int Med Den Res*. 2015;1(3):286–90.
- Kumar PA, Krishna CVM, Rao KS. Study of functional outcome of discectomy for lumbar disc prolapse. *J Evolution Med Dent Sci*. 2016;5(42):2597–602.
- Azimi P, Mohammadi HR, Montazeri A. An outcome measure of functionality and pain in patients with lumbar disc herniation: a validation study of the Japanese Orthop Association (JOA) score. *J Orthop Sci*. 2012;17(4):341–5.

## Author biography

**Saksham Sharma**, Assistant Professor

**Jiya Lal Bairwa**, Senior Resident

**Harishankar Meena**, Senior Resident

**Sachin Kumar Pachori**, Senior Resident

**Mahendra Singh Tak**, Assistant Professor

**Cite this article:** Sharma S, Bairwa JL, Meena H, Pachori SK, Tak MS. To study functional outcome of single level discectomy by fenestration method in lumbar disc prolapse- A prospective study. *IP Int J Orthop Rheumatol* 2023;9(1):46-50.