

Content available at: <https://www.ipinnovative.com/open-access-journals>

IP International Journal of Orthopaedic Rheumatology

Journal homepage: [www.ijor.org](http://www.ijor.org)

## Case Report

# Fracture neck of femur in severe coxa-vara – Challenging management in an Achondroplasia patient

Vishnu Senthil Kumar<sup>1,\*</sup>

<sup>1</sup>Dept. of Orthopedic Rheumatology, Govt. Royapettah Hospital, Chennai, Tamil Nadu, India



## ARTICLE INFO

### Article history:

Received 10-05-2022

Accepted 13-06-2022

Available online 02-07-2022

### Keywords:

Coxa Vara

Fracture neck of femur

Achondroplasia

## ABSTRACT

**Introduction:** Achondroplasia is a skeletal dysplasia of autosomal dominant inheritance. Fibroblast growth factor receptor 3 mutation at p16.3 locus of chromosome 4 leads to inhibition of sub-chondral growth. Middle aged achondroplastic patient with left fracture neck of femur following a fall of heavy object. It was a challenging case because of coxa-vara and meticulous templating is needed.

**Case Report:** 38 year old male sustained fracture neck of left femur in severe coxa-vara. Closed reduction with 16 mm partially threaded cannulated cancellous screw perpendicular to native neck- shaft angle. At regular follow up, mild lysis was seen around the screw and implant removal was done. Now with neck of femur non-union, walking full weight bearing with walker. The future course included excision arthroplasty or custom made prosthesis.

**Discussion:** Achondroplasia characterised by defects in en-chondral bone formation leading to retarded cartilage growth. Literature search on peri-articular fracture management showed paediatric disatal femur fracture fixed with percutaneous screws. In adult, neck of femur fracture is managed by percutaneous screw, DHS or prosthesis. Due to altered geometry of proximal femur DHS and Prosthesis was deferred. Early failure of CC screws in our case is due to perpendicular placement of screws which increased strain due to altered bio-mechanics.

**Conclusion:** Achondroplastic dwarfs live a normal life. They are prone to peri-articular fractures because of anatomical variations. We wanted to highlight the difficulties and importance of pre-op planning and implant choice of fracture fixation in an adult achondroplasia patient.

This is an Open Access (OA) journal, and articles are distributed under the terms of the [Creative Commons Attribution-NonCommercial-ShareAlike 4.0 License](https://creativecommons.org/licenses/by-nc-sa/4.0/), which allows others to remix, tweak, and build upon the work non-commercially, as long as appropriate credit is given and the new creations are licensed under the identical terms.

For reprints contact: [reprint@ipinnovative.com](mailto:reprint@ipinnovative.com)

## 1. Introduction

Achondroplasia is a common form of skeletal dysplasia which has autosomal dominant or sporadic inheritance.<sup>1</sup> Fibroblast growth factor receptor 3 (FGFR3) mutation found at p16.3 locus of chromosome 4 leads to inhibition of proliferation and terminal differentiation of chondrocytes affecting sub-chondral growth. FGFR3 dimers stabilized the mutation in the transmembrane domain preventing lysosomal degradation leading to continuous inhibition of chondrocyte proliferation. FGFR3 is critical for

chondrogenesis and osteogenesis and gain of function mutation in Achondroplasia lead to decreased bone mass and increased risk for fracture. FGFR3 also plays a pivotal role in fracture healing inhibiting initiation of chondrogenesis and hypertrophic differentiation of chondrocytes in soft callus.<sup>2</sup>

Anatomic variations include articular and peri-articular deformities which amplify the complexity of fracture fixation. Concomitant cardio-vascular, respiratory and neurological co-morbidities pose an additional risk during peri and post-operative period.

The estimated prevalence is 1:25,000 in general population but only few case reports are available in

\* Corresponding author.

E-mail address: [vishsnake@gmail.com](mailto:vishsnake@gmail.com) (V. S. Kumar).

literature that deal with orthopaedic fractures and problems associated with implant choice, internal fixation and healing.

Achondroplastic bone has a defect in enchondral ossification which affects the proliferative zone of the physis producing less chondrocytes for ossification. Proliferative zone stacks chondrocytes contributing to the longitudinal growth. Fracture healing consist of haematoma formation, soft callus, hard callus and re-modelling. Fracture healing occurs through intra-membranous or enchondral ossification. Rigid fixation of fracture heals with intra-membranous ossification and relative stability heals with callus by enchondral ossification. FGFR3 mutation has also showed delayed healing in rigid fixation.

We present a case of fracture neck of femur in an achondroplasia patient and its management. Achondroplastic patients can pose various medical and technical challenges and paucity of literature needs high degree of planning when faced with similar cases.<sup>3</sup>

## 2. Case Report

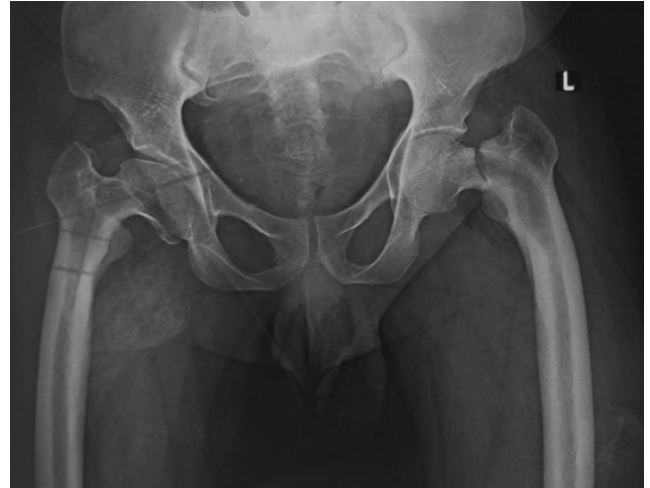38 year old male following fall of sintex tank over the left hip presented with fracture neck of femur in severe coxa-vara (Figure 1) Pre-operative planning was done and primary fracture fixation was decided upon. Prosthetic replacement was deferred because of young age and absent arthritic features. Implant choice was cannulated cancellous screw. Sliding hip screw system was deferred because of the abnormal geometry of the proximal femur. Patient had no co-morbidities. Closed reduction with two 16mm partially threaded cannulated cancellous screw with washer was done. The screws were placed perpendicular to the fracture site achieving absolute compression. Third screw was attempted but couldn't be placed because of the short and deformed neck (Figure 2).

Post-operatively patient was placed in non-weight bearing. 3 month follow up showed intact screws at compression site (Figure 3). At six month follow up, mild lysis was seen around the screw zone (Figure 4) and at 1 year follow up, screws started loosening (Figure 5). Implant removal was done. Now patient is at 18 month follow up, with neck of femur non- union (Figure 6). He is walking full weight bearing with walker with mild disability. The future course of events to be planned weather excision arthroplasty or custom made prosthesis to fit for the native femoral anatomy.

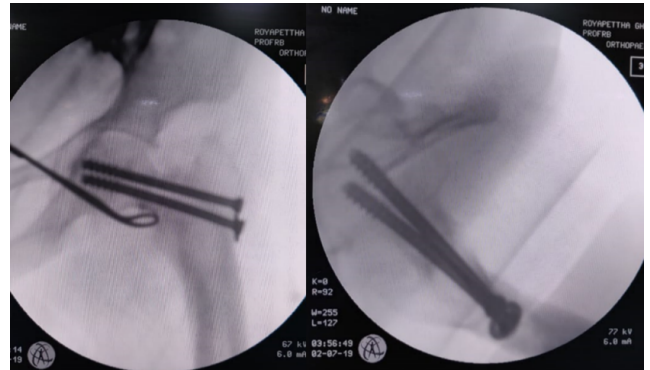
Figure 4:

## 3. Discussion

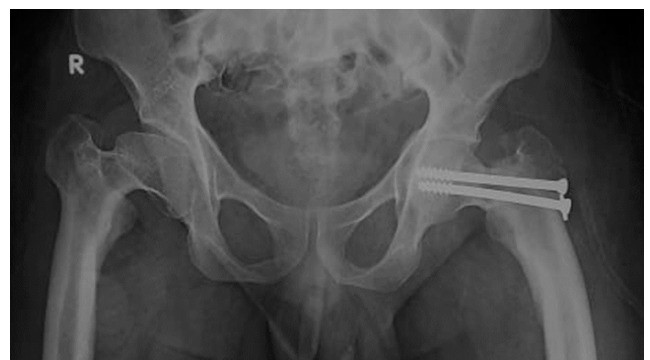Fracture neck of femur with bilateral severe coxa-vara of 90 degree poses a major technical challenge in the management. Achondroplasia is characterised by defects in en-chondral bone formation leading to retarded cartilage



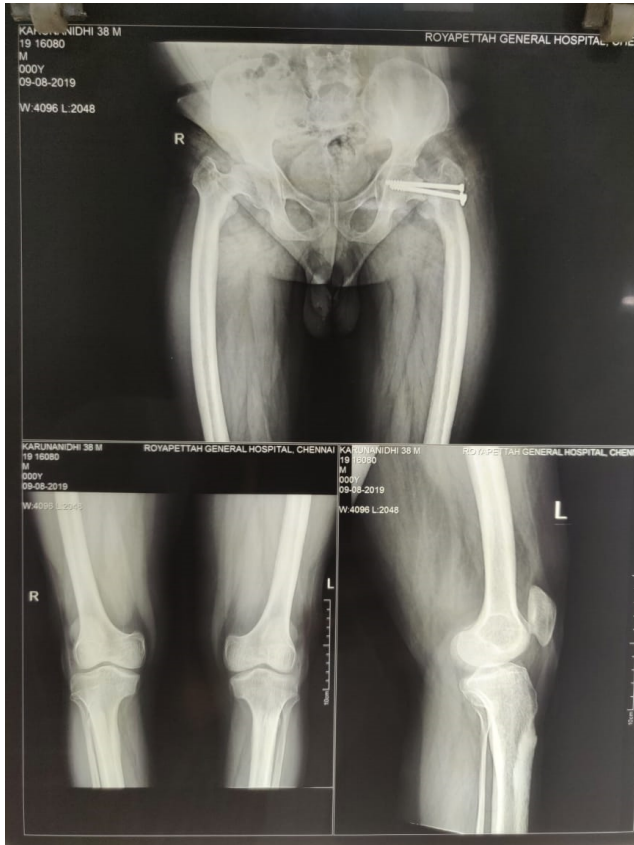
**Fig. 1:** Plain radiograph showing left fracture neck of femur in anachondroplasia patient with severe coxa- vara.



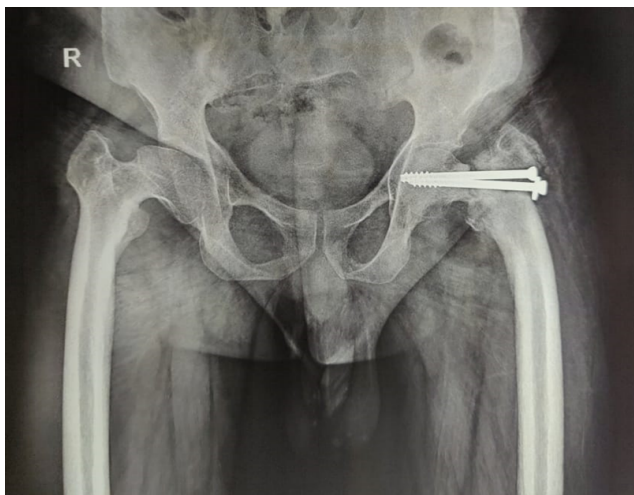
**Fig. 2:** Intra-operative C-ARM pictures showing fixation of Neck with cannulated cancellous screws achieving compression at fracture site



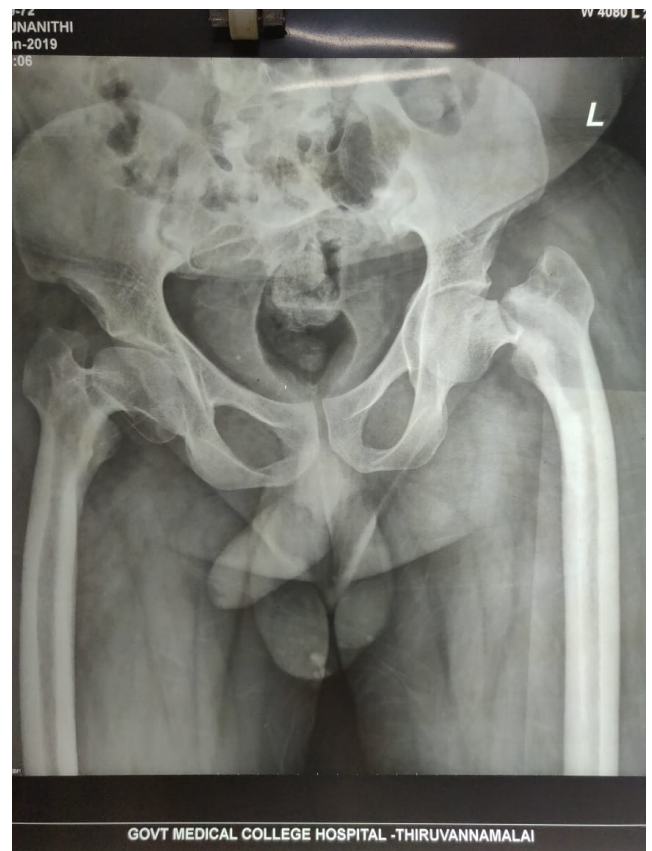**Fig. 3:** Plain radiograph with operated fracture neck of femur, compression maintained with cannulated cancellous screw at 3 month follow up with no loosening.



**Fig. 4:** Plain radiograph of pelvis at six month with operated left neck of femur showing osteolysis at fracture site and screw loosening.



**Fig. 5:** Plain Radiograph at one year follow up showing non-union at fracture site with osteo-lysis around screw site.



**Fig. 6:** Plain radiograph showing neck of femur non-union at 18 months follow up with good functional outcome.

growth, short-limb stature, Flared metaphysis, femoral head and acetabular asymmetry, metaphyseal angulation of knee and proximal femur leading to bowed deformities.<sup>3,4</sup>

Literature search of case reports on peri-articular fracture management in adult achondroplasia patients showed only one case report by murphy et al. In their case, they had fixed a distal femur with intra-articular extension (AO 33B2) fracture with only percutaneous screws since anatomical adult or paediatric distal femur locking plates couldn't match the patient's distal femur anatomy.<sup>5</sup>

In adults, fracture neck of femur is managed by percutaneous screw management, dynamic hip screw or prosthesis.<sup>6–8</sup> Dynamic hip screw was deferred because the bowed anatomy of proximal femur. Prosthesis replacement was not considered since young age, absence of arthritic features and altered geometry of the proximal femur for stem fixation.<sup>9,10</sup>

Healing in fracture neck of femur fracture occurs through compression at the fracture site. Cancellous bone possess much larger internal contact surface area with abundant blood supply with increased mesenchymal stem cells for differentiation and healing by intra-membranous ossification.

Early failure of screw fixation in our case was because of osteopenia, defective fracture healing due to defective chondral transformation to bone. Placement of cannulated cancellous screws perpendicular to the fracture site achieving compression but high pauwel's angle >90 deg led to high strain over the screws due abnormal bio-mechanics leading to screw loosening and failure of union at the fracture site.<sup>8</sup>

#### 4. Conclusion

Achondroplastic dwarfs generally live a normal life. They are also prone to peri-articular fractures because of anatomical variations in their bone. They might have un-diagnosed cardio-vascular and pulmonary co-morbidities which increase peri-operative risk.

We wanted to highlight the difficulties and importance of pre-op planning and implant choice of fracture fixation in an adult achondroplasia patient.

#### 5. Conflict of Interest

None.

#### 6. Source of Funding

None.

#### References

1. Horton WA, Hall JG, Hecht JT. Achondroplasia. *Lancet*. 2007;370(9582):162–72.
2. Rousseau F, Bonaventure J, Legeai-Mallet L, Pelet A, Rozet JM, Maroteaux P, et al. Mutations in the gene encoding fibroblast growth factor receptor-3 in achondroplasia. *Nature*. 1994;371(6494):252–4.
3. Carter EM, Davis JG, Raggio CL. Advances in understanding etiology of achondroplasia and review of management. *Curr Opin Pediatr*. 2007;19(1):32–7. doi:10.1097/MOP.0b013e328013e3d9.
4. Laederich MB, Horton WA. Achondroplasia: pathogenesis and implications for future treatment. *Curr Opin Pediatr*. 2010;22(4):516–23.
5. Murphy CG, Chrea B, Molloy AP. Small is challenging; distal femur fracture management in an elderly lady with achondroplastic dwarfism. *BMJ Case Rep*. 2013;doi:10.1136/bcr-2013-008793.
6. Khoo C, Haseeb A. Ajit Singh V. Cannulated Screw Fixation For Femoral Neck Fractures: A 5-year Experience In A Single Institution. *Malays Orthop J*. 2014;8(2):14–21. doi:10.5704/MOJ.1407.010.
7. Bosch U, Schreiber T, Krettek C. Reduction and fixation of displaced intracapsular fractures of the proximal femur. *Clin Orthop Relat Res*. 2002;(399):59–71. doi:10.1097/00003086-200206000-00009.
8. Graham J. Early or delayed weight-bearing after internal fixation of transcervical fracture of the femur. A clinical trial. *J Bone Joint Surg Br*. 1968;50(3):562–9.
9. Arita ES, Pippa MG, Marcucci M, Cardoso R, Cortes AR, Watanabe PC, et al. Assessment of osteoporotic alterations in achondroplastic patients: a case series. *Clin Rheumatol*. 2013;32(3):399–402.
10. Chiavetta JB, Parvizi J, Shaughnessy WJ, Cabanela ME. Total Hip Arthroplasty in Patients with Dwarfism. *J Bone Joint Surg Am*. 2004;86(2):298–304. doi:10.2106/00004623-200402000-00012.

#### Author biography

Vishnu Senthil Kumar, Senior Resident

**Cite this article:** Kumar VS. Fracture neck of femur in severe coxa-vara – Challenging management in an Achondroplasia patient. *IP Int J Orthop Rheumatol* 2022;8(1):29-32.