

Content available at: <https://www.ipinnovative.com/open-access-journals>

IP International Journal of Orthopaedic Rheumatology

Journal homepage: [www.ijor.org](http://www.ijor.org)

## Case Report

# Ochronotic Knee Arthropathy: A rare cause of arthritic knee pain and literature review of surgical considerations during knee arthroplasty

Lavindra Tomar<sup>1</sup>, Gaurav Govil<sup>1,\*</sup>, Pawan Dhawan<sup>1</sup><sup>1</sup>Dept. of Orthopaedics, Max Super Speciality Hospital, Patparganj, Delhi, India

## ARTICLE INFO

### Article history:

Received 18-10-2020

Accepted 22-12-2020

Available online 15-01-2021

### Keywords:

Alkaptonuria

Ochronosis

Arthropathy

Black joints

Knee arthroplasty.

## ABSTRACT

**Introduction:** Knee osteoarthritis is a common disabling affection in the elderly. Rarely the arthritis of knee may be due to ochronotic arthropathy. It is often missed or misdiagnosed as osteoarthritis. An autosomal recessive metabolic disorder characterized by the deficiency of homogentisic acid oxidase enzyme preventing metabolism of homogentisic acid lead to homogentisic aciduria. Alkaptonuria progresses to ochronotic degeneration and arthritis. Early management of ochronotic arthropathy is challenging and is mainly limited to control of symptoms. Advanced cases may necessitate surgery.

**Case Report:** A 65-year-old male presents with persistent progressive pain in both knees, not responding to conservative measures. Patient required simultaneous bilateral cemented total knee arthroplasty for management of arthritic knee pain. Arthrotomy revealed black joints with pigment deposition throughout the articular cartilage and neighboring tissues. Meticulous surgical technique allowed uneventful procedure. Postoperatively patient gained pain-free functional knee movements and was able to ambulate without support within six weeks of arthroplasty. The Knee Society Score improved to 95 bilaterally. At two years, radiologically there was good alignment with no loosening.

**Discussion:** Arthroplasty is an excellent choice for patients with ochronotic arthropathy. However, more information and experience are needed for uniform implant selection and techniques. We report this rare, often missed cause of common knee pain. We review the literature to discuss the specific surgical considerations during knee arthroplasty in such an unusual presentation.

This is an Open Access (OA) journal, and articles are distributed under the terms of the [Creative Commons Attribution-NonCommercial-ShareAlike 4.0 License](https://creativecommons.org/licenses/by-nc-sa/4.0/), which allows others to remix, tweak, and build upon the work non-commercially, as long as appropriate credit is given and the new creations are licensed under the identical terms.

For reprints contact: [reprint@ipinnovative.com](mailto:reprint@ipinnovative.com)

## 1. Introduction

Knee arthritis is a common cause of chronic knee pain and disability in adults and elderly. Degenerative osteoarthritis, rheumatoid or gouty arthritis are common causes of knee arthropathy. Uncommon metabolic disorders are often missed or diagnosed late. Conservative strategies to manage knee arthropathy include pain relief measures using non-steroidal anti-inflammatory medications, life style modifications, intraarticular injections, strengthening exercises and braces. Surgery for non-responders require

arthroplasty.

A rare autosomal recessive metabolic disorder like alkaptonuria may often cause significant knee pain.<sup>1–5</sup> The deficiency of the enzyme homogentisic acid oxidase leads to accumulation of homogentisic acid, an intermediary in metabolism of phenylalanine and tyrosine.<sup>4,6,7</sup> It affects one in 250,000 to 1,000,000 individuals.<sup>2,3</sup> The deposition of oxidized homogentisate pigments in connective tissues affects the articular cartilages.<sup>1,3</sup> It leads to chronic inflammation, degeneration, and eventually arthritis.<sup>1,3</sup> Patients with alkaptonuria usually do not show any symptoms and about fifty percent develop ochronotic arthritis. Ochronotic arthropathy becomes symptomatic

\* Corresponding author.

E-mail address: [gauravgovil@yahoo.co.in](mailto:gauravgovil@yahoo.co.in) (G. Govil).

around fourth decade.<sup>1,4</sup> Men are affected more commonly than women.<sup>4</sup> The knee being the commonest site of arthropathy with hip, shoulder and sacroiliac joint may also be involved.<sup>1,4,5</sup> The general approach is to manage symptoms as they present.<sup>1,5</sup> Exercise and analgesics have beneficial effect but it does not slow the degeneration of joint and progression of arthropathy. When significant degenerative arthritis occurs, arthroplasty gives excellent outcomes comparable to osteoarthritis.<sup>1,4</sup>

A case of knee pain in a 65-year-old male incapacitated by arthritis of both knees with poor response to conservative measures is presented. A non-responder to conservative measures required simultaneous bilateral knee arthroplasty for relief from his persistent disabling knee pain.

## 2. Case Report

A 65-year-old male patient presented with history of progressive persistent pain in both knee joints with limited walking ability for last two years. Anti-inflammatory medications, physiotherapy sessions and multiple intra-articular steroid injection yielded no benefit. Patient was diagnosed with alkaptonuria at the age of 40 years. There was a history of intermittent passage of blackish colored urine since childhood. There was no positive family history of the disease. He had past history of spine decompression, cardiac bypass grafting and renal stone surgery.

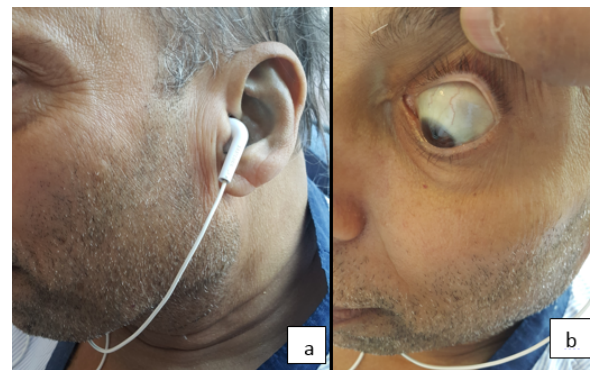Examination revealed a short stature with grayish discoloration of the ear pinnae (Figure 1a) and sclera (Figure 1b). Patient had moderate varus aligned bilateral knees with effusion. He could barely walk and had an unstable gait with antalgic component. Range of motion was 10° to 80° of knee flexion bilaterally. There was knee instability associated with lax collateral ligaments. Distal neurovascular examination was normal.

Radiographs of both the knee showed significant medial joint space loss with lateral and patellofemoral degenerative changes (Figure 2a, b & c). Radiograph of the spine revealed intervertebral disc space calcification with degenerative changes (Figure 2d and 2 e).

A simultaneous bilateral knee arthroplasty was performed using an anterior medial parapatellar approach. On arthrotomy, the subcutaneous tissues revealed black nodular deposit and extension of arthrotomy revealed hypertrophied synovium. The contracted joint capsule was gritty to incise with minimal joint fluid but extensively blackened articular knee cartilage (Figure 3a). The patella was carefully retracted laterally in apprehension of tendon rupture on forceful retraction. Total synovectomy was done and blackened stiff meniscal pads inside the joints were noted (Figure 3b). Generalized degeneration throughout the knee with extensive articular cartilage loss was observed. The subchondral bone while taking bone cuts revealed black discoloration (Figure 3c). After knee resurfacing, drill holes were made on femur and tibia (Figure 3d). Standard

cementing technique was used and a cruciate sacrificing, cemented Depuy PFC Sigma, Johnson and Johnson (USA) arthroplasty was done along with patellar resurfacing and deformity correction (Figure 3e). Intraarticular tranexamic acid was used to minimize blood loss. Mobilization in immediate postoperative period was done and wound healing was uneventful. A good functional range of motion was regained and independent daily activities within six weeks of surgery was achieved. At three months, the arc of motion was pain-free up-to 110° of flexion without extensor lag in both knees. At 24 months follow up, there was stable and pain-free ambulation with an improved KSS score of 95 for both knees (Figure 4a & b).

Postoperative radiographs (Figure 5a, b & c) showed components in good alignment with no evidence of component loosening. Patient outcome was evaluated and was considered to be satisfactory. The patient gave informed consent for use of data for publication

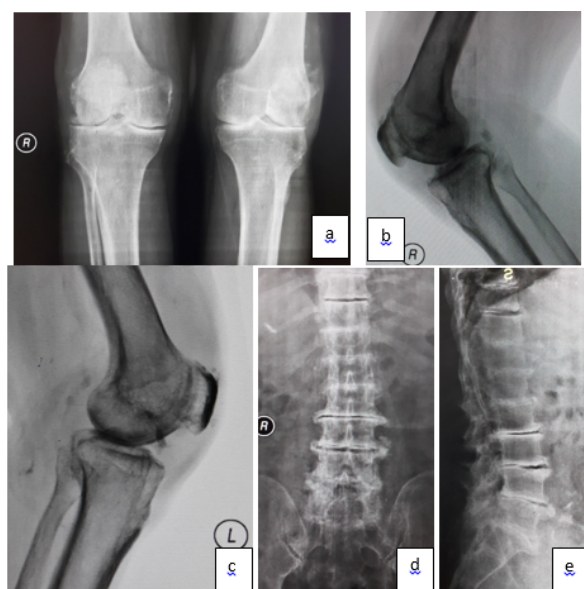

**Fig. 1:** Clinical photograph, **1a:** black pinna, **1b:** black sclera

## 3. Discussion

Wolkow and Baumann identified the chemical structure of alkapton as homogentisic acid in 1891. In 1902, Garrod presented evidence that the condition is congenital and familial and occurs more often in families in which there are consanguineous marriages.<sup>1</sup> In 1902, Albrecht and Zdarek, interrelated the terms alkaptonuria and ochronosis.<sup>8</sup>

It takes three to four decades before homogentisic acid accumulates in tissues to cause clinical symptoms.<sup>2,9</sup> Accumulation of homogentisic acid and binding to fibrillar collagen becomes irreversible after polymerization however renal tubular excretion system efficiently secretes homogentisic acid. The metabolic disorder passes through three clinical stages of which first being black staining of the clothes getting noticed, second being alkaptonuric ochronosis characterized by pigmentation of various tissues of the body and lastly ochronotic arthritis involving spine and large peripheral joints.<sup>7</sup>



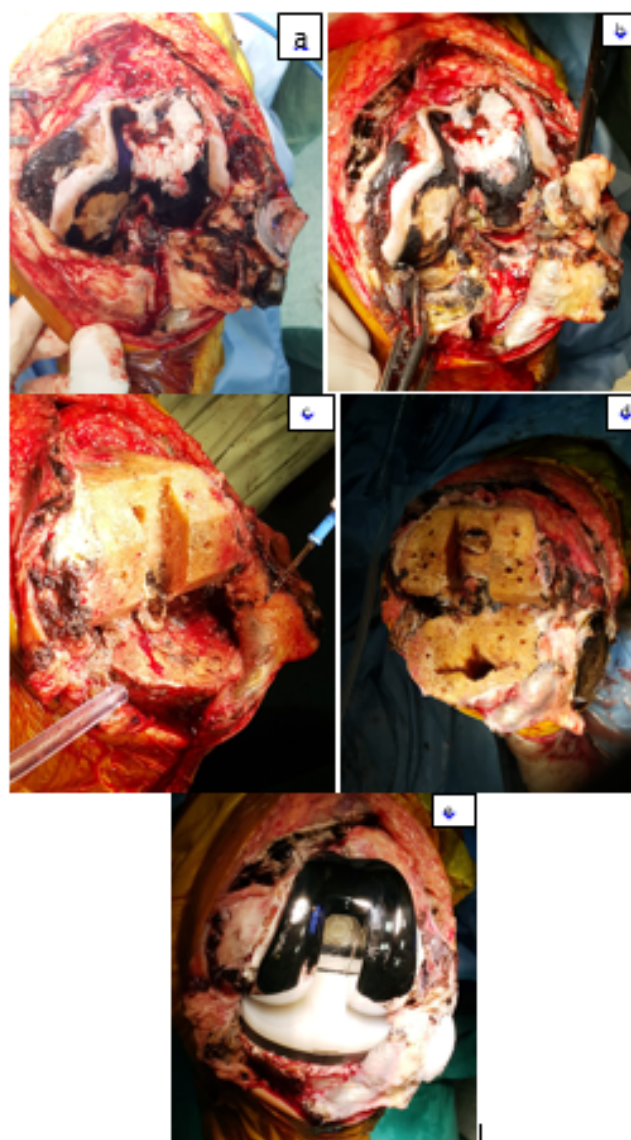
**Fig. 2:** Preoperative, **2a:** anteroposterior radiograph of knees, **2b:** lateral radiograph of right knee, **2c:** lateral radiograph of left knee, **2d:** anteroposterior radiograph of lumbosacral spine, **2e:** lateral radiograph of lumbosacral spine.

Clinical manifestations of ochronosis includes dark brownish pigmentation of connective tissue such as sclera, ear, laryngeal, tracheal, and meniscus cartilage, darkening of urine after long-term exposure to air, major joint arthropathy, spondyloarthropathy, cardiac valve disease, nephro-calcinosis and renal dysfunction.<sup>2,8</sup> Knee and hip are the frequently affected joint. Radiographic changes in the large peripheral joints specially knee joints, are generally observed ten years after spinal changes. Like in patients with primary osteoarthritis, radiographic changes include joint space narrowing, small osteophytes and subchondral sclerosis.<sup>4</sup>

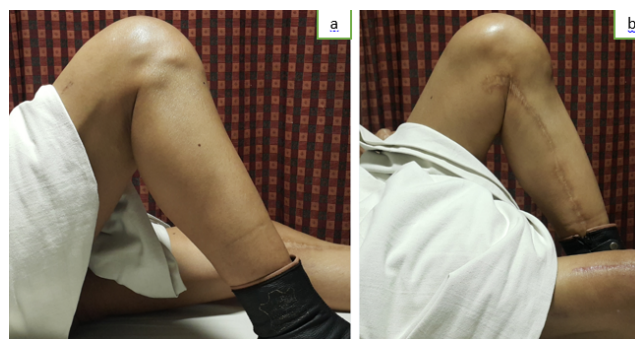There are no known medicines to treat alkaptonuria. The surgical treatment for ochronotic arthritis is described in few case reports with short follow-up.<sup>3</sup> Knee arthroplasty has been considered as an option of management but few considerations during surgery to avoid intraoperative difficulties have been reviewed.

Preoperative assessment of medical comorbidities may avoid unsuspecting complications. Evaluation of history for associated degenerative spine disease, heart, renal, ophthalmic and prostate related issues should be considered before a planned arthroplasty. The pain management by epidural medication or block application have increased relevance.

Tendon ruptures may complicate the arthroplasty. Difficulties in displacing the patella as reported by Spencer et al. are indicative of quadriceps and patellar tendon hardening.<sup>3</sup> Popping sound as noticed by Patel et al can be a sign of tear or detachment.<sup>1</sup> Tendon can be friable, stiff and

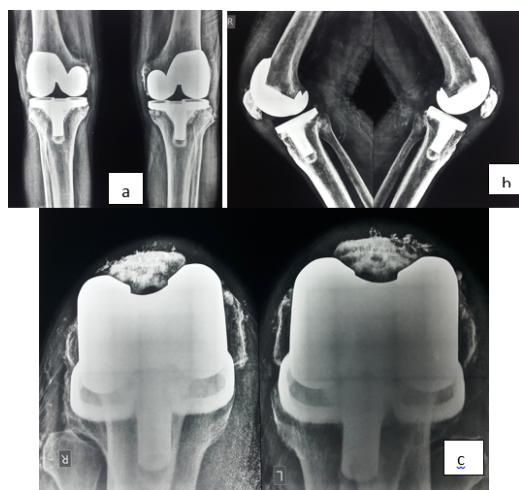


**Fig. 3:** Intraoperative, **3a:** blackened joint surfaces, **3b:** blackened thick calcified menisci, **3c:** subchondral bone pigment deposition, **3d:** drill holes femur and tibia before cementing, **3e:** implanted total knee prosthesis.



**Fig. 4:** Postoperative clinical photograph at 2 year follow up, **4a:** right knee flexion, **4b:** left knee flexion.





**Fig. 5:** Postoperative radiograph of knees at 24 months, **5a:** anteroposterior view, **5b:** lateral view, **5c:** skyline view.

prone to ruptures due to connective tissue disarray.<sup>9</sup>

Bone quality is a matter of concern. The osteoporosis may compromise and perioperative fractures may occur. Cuts should be made carefully. A cemented arthroplasty should be considered because of bone softness. There is limited data on use of uncemented prosthesis for ochronotic arthropathy. Kontinen et al and Aydogdu et al, performed cement less arthroplasty as the quality of bone was considered good.<sup>2,5</sup> The long-term survival of these implants has not been reported.<sup>2</sup> Fisher and Davis reported multiple fractures in their case although they found no associated risk factor with bone health.<sup>5</sup>

Blood loss may be excessive both intra and postoperatively.<sup>1</sup> Intraarticular and systemic use of tranexamic acid may be considered to decrease blood loss. Use of drains for prolonged period was suggested by Patel et al. The use of blood substitutes may be required.

Simultaneous or sequential arthroplasty may be debated. Interestingly, most of the cases in the literature had been treated by bilateral arthroplasty.<sup>5</sup> Spencer et al, did eleven arthroplasties in both upper and lower limbs in three patients with end-stage ochronotic large joint degenerative disease, with good clinical results and no evidence of implant failure or complications on long term follow up.<sup>3</sup>

There is lack of uniformity in reporting the outcome of cases. Spencer et al had satisfactory results in their three cases.<sup>5</sup> However, only Aydogdu et al reported pre- and postoperative knee scores. The uniform reporting on knee scores will strengthen the outcome assessment.

Knee arthroplasty in a patient with significant degenerative arthritis secondary to ochronosis had excellent outcomes.<sup>4,5,10</sup> Awareness of this rare but easily recognizable condition is necessary, to avoid confusion with degenerative osteoarthritis.

#### 4. Conclusion

Ochronotic arthritis is a rare disorder with challenges in management and limited to alleviating the knee pain. Advanced ochronotic arthritis necessitate arthroplasty. The type of prosthesis used depends on surgeon's preference and individual characteristics of bone and soft tissue. We need more uniform detailed information to convert experience to real knowledge.

#### 5. Conflict of interest

We declare there is no conflict of interest.

#### 6. Source of Funding

We declare that this study has not received any funding from agencies in the public, commercial, or not-for-profit sectors.

#### References

1. Patel VG. Arthroplasty in patients with rare conditions- Total knee arthroplasty in ochronosis. *Arthroplasty Today*. 2015;1:77–80.
2. Miyazaki T, Kokubo Y, Kobayashi S, Sato T, Uchida K, Bangirana A. Ochronotic Arthropathy Requiring Bilateral Hip and Knee Joint Arthroplasty: Case Study. *XXV*. 2006;XXV(4):489–96.
3. Spencer J, Gibbons CLM, Sharp R, Carr A, Athanasou N. Arthroplasty for ochronotic arthritis: No failure of 11 replacements in 3 patients followed 6–12 years. *Acta Orthop Scand*. 2004;75(3):355–8. doi:10.1080/00016470410001321.
4. da Silva Martins Ferreira AM, Santos FL, Costa AMC, Barbosa BP, Rocha RR, Lebre JF, et al. Osteoartrite do joelho secundária a ocrinose – Caso clínico. *Rev Bras Ortop*. 2014;49(6):675–80. doi:10.1016/j.rbo.2013.11.003.
5. Özmanevra R, Güran O, Karatosun V, Günel I. Total knee arthroplasty in ochronosis: a case report and critical review of the literature. *Joint Dis Related Surg*. 2013;24(3):169–72. doi:10.5606/ehc.2013.36.
6. Chang SS, Ek ET, Pliatsios V. Black bones: a case of incidental discovery of ochronotic arthropathy. *Med J Aust*. 2009;190:390. doi:10.5694/j.1326-5377.2009.tb02456.x.
7. Pratibha K, Seenappa T, Ranganath K. Alkaptonuric ochronosis: Report of a case and brief review. *Indian J Clin Biochem*. 2007;22(2):158–61. doi:10.1007/bf02913337.
8. Xu H, Wang J, Chen F, Hong Z, Zhang X, Ji X, et al. Ochronotic arthritis of bilateral knees: a case report. *Int J Clin Exp Med*. 2015;8(5):8185–9.
9. Sahoo MM, Mahapatra SK, Sethi GC, Dash SK: Patellar ligament rupture during total knee arthroplasty in an ochronotic patient -case report. *Acta Orthop Traumatol Turc*. 2014;48(3):367–70.
10. Haruna M, Hayrettina Y, Serhatb M, Firata MCF, Ufuka O. A rare cause of arthropathy: An ochronotic patient with black joints. *Int J Surg Case Rep*. 2014;5:554–7.

#### Author biography

**Lavindra Tomar**, Director and Unit Head

**Gaurav Govil**, Senior Consultant

**Pawan Dhawan**, Attending Consultant

**Cite this article:** Tomar L, Govil G, Dhawan P. Ochronotic Knee Arthropathy: A rare cause of arthritic knee pain and literature review of surgical considerations during knee arthroplasty. *IP Int J Orthop Rheumatol* 2020;6(2):88-91.